

## Delayed Post-Operative Pneumoperitoneum

Adil Ceydeli<sup>a</sup>, Bashar Fahoum<sup>a</sup>, Moshe Schein<sup>b,c</sup>

Departments of Surgery, <sup>a</sup>New York Methodist Hospital, Brooklyn, <sup>b</sup>Bronx Lebanon Hospital Center, Bronx, N.Y., and <sup>c</sup>Weill Medical College of Cornell University, New York, N.Y., USA

### Key Words

Post-operative pneumoperitoneum, delayed

### Abstract

We present a case of post-operative pneumoperitoneum (PP), which persisted for eight weeks. Postoperative retained air is the most common cause of PP. It does not require a surgical intervention and thus is defined as a 'non-surgical PP'. The etiological factors contributing to the duration of the postoperative PP are controversial but the longest time described in the literature is 24 days. We review the relevant literature and discuss factors contributing to the duration of postoperative PP.

Copyright © 2002 S. Karger AG, Basel

### Introduction

Pneumoperitoneum (PP) is free air in the peritoneal cavity. Iatrogenic postoperative retained air is the most common cause of PP. In patients who have not had a recent laparotomy or laparoscopy the

most common cause of PP (90%) is a perforated viscus ('surgical PP'), followed by numerous 'non-surgical' causes (10%) summarized in table 1 [1–4].

In most instances postoperative PP resolves within a week, but there are reported cases of PP lasting as long as 10–24 days [5–10]. In order to prevent negative laparotomies it is important to differentiate the post-operative delayed PP from 'surgical PP'.

We present herein a case of postoperative delayed PP which persisted for eight weeks. This is the longest duration of PP reported in the literature.

Table 1. 'Non-surgical' causes of pneumoperitoneum

	References
<i>Thoracic</i>	
Intermittent positive-pressure ventilation causing barotrauma	1, 2, 3, 4
Tracheal rupture (may require surgery)	3
Asthma	1, 2
Bronchoscopy	2, 4
Cardiopulmonary resuscitation	2, 3
Adenotonsillectomy	2
Pulmonary tuberculosis	2
Blunt chest trauma	2, 3
Bronchopulmonary fistula	2
Spontaneous rupture of pulmonary blebs	2
<i>Abdominal</i>	
Pneumatosis cystoides intestinalis	1, 2, 3, 4
Endoscopic procedures	2, 4
Spontaneous bacterial peritonitis	3
Peritoneal dialysis	3
Postpolypectomy syndrome	2
Pneumocholecystitis	2
Jejunal and sigmoid diverticulosis	1, 2
Distended hollow viscus	2
Splenic embolization	3
<i>Gynecological</i>	
Vaginal insufflation	1, 2, 3, 4
Gynecologic examination procedures	1, 2, 4
Ovarian cancer	3
Pelvic inflammatory disease	2
Coitus	2
Oral sex	1
Vaginal douching	1
Knee-chest exercises	1, 2
<i>Miscellaneous</i>	
Cocaine use	3
Diving with decompression	3
Dental extraction	3
Collagen vascular disease	1, 3
Idiopathic	2, 3

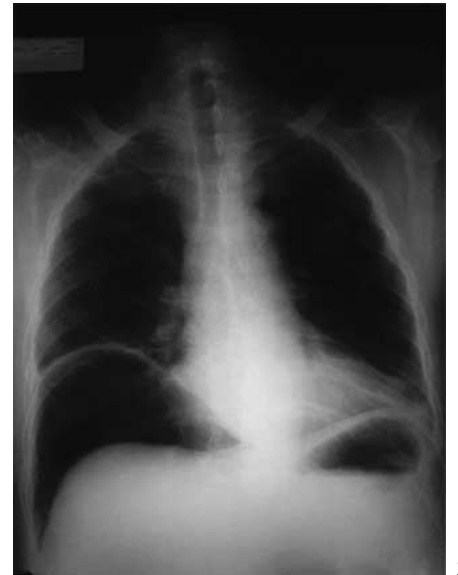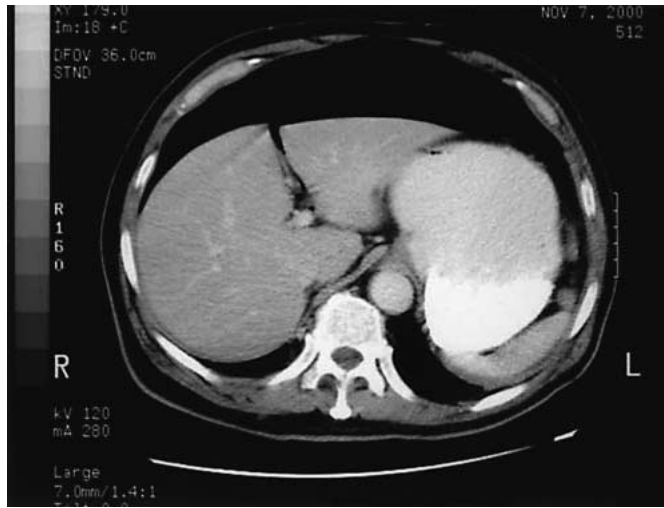


Fig. 1. Abdominal CT scan of the patient 4 weeks after surgery.  
Fig. 2. Repeat chest X-ray of the patient 8 weeks after surgery.

Table 2. Duration of postoperative pneumoperitoneum and contributing factors

Authors Reference	Patients in study groups	Longest duration of PP	Proposed contributing factors
Bryant et al. [5]	194	24 days	BMI, initial amount of free air, general anesthesia with muscle relaxation, type of incision, postoperative complications
Bevan [6]	82	15 days	Gender, BMI, initial amount of free air, type of abdominal surgery, early ambulation
Harrison et al. [7]	104	23 days	Initial amount of free air, type of abdominal surgery, BMI, type of incision
Gayer et al. [8]	89	18 days	Gender, BMI, presence of drains
Tang et al. [9]	75	10 days	None
Ein et al. [10]	88 <sup>a</sup>	19 days	Age, weight, type of incision, duration of surgery, wound infection
Nielsen et al. [11]	32	longer than 5 days	Initial amount of free air, BMI

<sup>a</sup> Pediatric patients.

### Case Report

A 59-year-old male, who had a past surgical history of right hemicolectomy for adenocarcinoma of the cecum, was admitted 18 months later with a recurrent proximal transverse colon tumor with anastomotic site involvement. As the CT scan showed no evidence of carcinomatosis or metastases the patient was subjected to an exploratory laparotomy and a transverse colectomy including the previous anastomosis. The postoperative course was unremarkable and the

patient was discharged in a stable condition. He was readmitted one month after the operation with acute urinary retention but without fever or leukocytosis. Chest X-ray revealed free air under the diaphragm. Both the CT scan (fig. 1) and the gastrografin enema, which were obtained to rule out a visceral perforation or an anastomotic leak, were negative, establishing thus the diagnosis of delayed postoperative PP. The urinary retention was treated and the patient was discharged. A repeat chest X-ray (fig. 2), which was performed two months after the operation, still showed persistent free air under the

diaphragm, again in the absence of any abdominal symptoms or signs and elevated temperature or white cell count.

## Discussion

There are a number of reports looking at the etiology, duration and contributing factors concerning postoperative PP as indicated in table 2, but the exact duration of postoperative PP still remains controversial. Consequently, postoperative PP may be confused with 'surgical PP'—resulting in negative laparotomies. Since there is no universal opinion as to the duration of postoperative PP, it is important to correlate the radiological findings with the clinical symptoms and signs before deciding on a therapeutic approach.

Bryant et al. [5] presented a patient with a 24-day duration of PP, this being the longest in the literature, and pointed out the effects of body mass index (BMI), initial amount of free air, general anesthesia with muscle relaxation, type of incision and postoperative complications on the duration of postoperative PP. Bevan [6] presented a patient with a 15-day duration of postoperative PP, this being the longest in the series, whereas Harrison et al. [7] reported the duration of postoperative PP as 23 days after gastrectomies, and pointed out that the type of the abdominal surgery influenced the duration of postoperative PP, upper abdominal surgeries, particularly gastrectomies having the longest one. Gayer et al. [8] presented a series of 89 patients who underwent 92 abdominal operations, in which 18 days was the longest period of time until the free air disappeared. They found that free air was significantly more often present in men and asthenic patients, but they could not demonstrate an effect of age and the type of the procedure on the duration of postoperative PP. Tang et al. [9] studied 75 consecutive patients for postoperative free air, and 89% of the patients had no free air by the postoperative first week, while only 6% had retained air by postoperative day 10. They could not show any significant effect of duration of surgery, BMI, postoperative ileus and drainage catheters on the disappearance of free air postoperatively. Ein et al. [10] looked at 88 pediatric surgical patients, in whom the longest duration of postoperative free air was 19 days. Nielsen et al. [11] studied 32 post-laparotomy patients; 63% had no free air after the second day, and only one patient (3%) had persistent PP for longer than 5 days. The duration of postoperative PP was not influenced by the nature of the procedure (laparotomy vs. laparoscopy), the duration of operation, the length of the incision, the presence of peritonitis, intraperitoneal adhesions, drains, and stomas, whereas their data confirmed other studies [5–7], indicating that the initial amount of air introduced to the peritoneum during surgery and the BMI of the patients had a significant effect on the duration of PP, being the longest in the low BMI patients.

Postoperative PP is a 'non-surgical' PP and is the commonest cause of free air in patients after a laparotomy. It is crucial to differentiate this entity from 'surgical PP', in order to prevent negative laparotomy with its morbidity and mortality. An up-right chest X-ray is the simplest and cheapest diagnostic tool to detect intra-abdominal free air, whereas CT scan of the abdomen is the most sensitive diagnostic test and may be helpful to detect very small amounts of free air if clinically indicated. The type and the duration of operation, the length of the incision, the initial amount of air introduced during surgery, presence of adhesions, drains, and stomas, age, gender and BMI of the patients are among the many proposed contributing factors to the duration of postoperative PP [5–8, 10, 11].

Regardless of the contributing factors, non-surgical postoperative PP may last as long as eight weeks as presented above, and the clinical correlation with radiological findings, as well as history, are crucial when deciding whether a laparotomy is indicated or not.

## References

- 1 Mezghebe HM, Leffall LD Jr, Siram SM, Syphax B: Asymptomatic pneumoperitoneum diagnostic and therapeutic dilemma. *Am Surg* 1994;60:691–694.
- 2 Mularski RA, Ciccolo ML, Rappaport WD: Nonsurgical causes of pneumoperitoneum. *WJM* 1999;170:41–46.
- 3 Mularski RA, Sippel JM, Osborne ML: Pneumoperitoneum: A review of nonsurgical causes. *Crit Care Med* 2000;28:2638–2644.
- 4 Madura MJ, Craig RM, Shields TW: Unusual causes of spontaneous pneumoperitoneum. *Surg Gynecol Obstet* 1982;154:417–420.
- 5 Bryant LR, Wiot JF, Kloecker RJ: A study of the factors affecting the incidence and duration of postoperative pneumoperitoneum. *Surg Gynecol Obstet* 1963;117:145–150.
- 6 Bevan PG: Incidence of postoperative pneumoperitoneum and its significance. *Br Med J* 1961;2:605–609.
- 7 Harrison I, Litwer H, Gerwig WH: Studies on the incidence and duration of postoperative pneumoperitoneum. *Ann Surg* 1957;145:591–594.
- 8 Gayer G, Jonas T, Apter S, Amitai M, Shabtai M, Hertz M: Postoperative pneumoperitoneum as detected by CT: prevalence, duration, and relevant factors affecting its possible significance. *Abdom Imaging* 2000;25:301–305.
- 9 Tang CL, Yeong KY, Nyam DC, Eu KW, Ho YH, Leong AF, Tsang CB, Seow-Choen F: Postoperative intra-abdominal free gas after open colorectal resection. *Dis Colon Rectum* 2000;43:1116–1120.
- 10 Ein SH, Clinton AS, Bernard JR: The disappearance of free air after pediatric laparotomy. *J Pediatr Surg* 1985;20:422–424.
- 11 Nielsen KT, Lund L, Larsen LPS, Knudsen P: Duration of postoperative pneumoperitoneum. *Eur J Surg* 1997;163:501–503.

Moshe Schein, MD

Department of Surgery, Bronx-Lebanon Hospital Center  
1650 Selwyn Ave, 4th Floor, Suite 4F, Bronx, NY 10457 (USA)  
Tel. +1 718 960 1295, Fax +1 718 960 1312

E-Mail mschein1@mindspring.com