

Mag-5: a Magnificent Approach to Upper and Midfacial “Magic”

Robert S. Flowers, MD^{a,*}, Adil Ceydeli, MD, MS^{a,b}

KEYWORDS

- Mag-5 canthopexy • Corono-canthoplasty
- Two layered (into the bone) canthopexy
- Extended canthopexy • Vertical dystopia
- Lower lid shortening • Lower lid laxity
- Scleral show (vertical dystopia of lower lid)
- Anti-mongoloid tilt • Tear trough deformities
- Naso-jugal grooves

In the early 1970s, the senior surgeon (RSF) experienced three epiphanies, all of a surgical nature, each of which radically changed his approach to esthetic surgery. Over the years these three discoveries coalesced into one awesome operation that for 30 plus years has done wonders in solving the varied and often difficult problems commonly encountered by plastic surgeons¹⁻⁷ (and those not so commonly encountered) in the forehead-brow, periorbital and temple areas, scalp, lower lids, malar, and lower midcheek region. As these three epiphanies or “discoveries” coalesced, the quality of patient outcomes soared (**Fig. 1**).

The first epiphany dealt with the upper lids. It became clear that an aggressive tissue removal, that is, the traditional four-lid blepharoplasty depicted in **Fig. 2**, is typically a deforming operation.⁸ The senior author did this operation shown in **Fig. 2** in 1969 using essentially the same techniques most of us learned, even though they invariably cause a drop of the brow, exaggeration of the corrugator frown, vertical dystopia of the lower lid, and rounding of the aperture.⁹ **Fig. 3** shows a mature gentleman who underwent a four-lid blepharoplasty almost 2 decades later in 1986, (but with canthal support) who declined the recommended frontal lift until he experienced the profound effect of not having one. The inevitable drop of the brow after an upper

blepharoplasty makes a person look older, more tired, and angry as well,¹⁰ advancing a frontal lift with corrugator resection (as we eventually did for this patient) to the “front of the line” as the preferred or, at very least, an essential companion operation (**Fig. 3C**)¹¹⁻¹³ for treating the vast majority of baggy or saggy upper lids. This predictable deformity caused by upper lid resection or invagination is due to the pervasiveness of “compensated brow ptosis.”¹⁴ This is the title given to a ptotic resting brow forced into a perpetually raised position by the need for comfortable and unobstructed vision. When compensated brow ptosis exists, there will always be a correspondingly profound drop of the brow (and frown accentuation) following upper blepharoplasty.¹⁵

The reason why we connect these brow and upper lid modifications with lower lid and midfacial corrections becomes apparent in the patient shown in **Fig. 4A**. She is 49 years old, with no previous surgery but with a lot of compensated brow ptosis. Her coronal lift and corrugator resection, which was responsible for much of her improvement (**Fig. 4**), opened the door for the rest of her correction, first, by providing superb access to the frown muscles and orbital rims and, second, by raising the droopy lateral brow and temple skin. This second part is absolutely essential for preventing crowding when we do

^a The Flowers Clinic, 677 Ala Moana Boulevard, Suite 1011, Honolulu, HI 96813, USA

^b Bay Medical Center, 801 East 6th Street, Suite 302, Panama City, FL 32401, USA

* Corresponding author.

E-mail address: flowers@flowersclinic.com (R.S. Flowers).

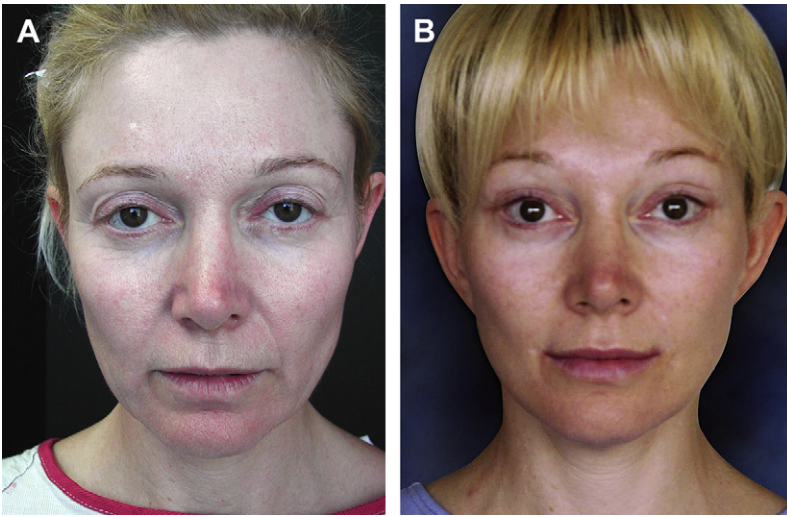

Fig. 1. A 56-year-old woman shown (A) before and (B) 2 years after Mag 5, the coalesced outcome of three epiphanyes.

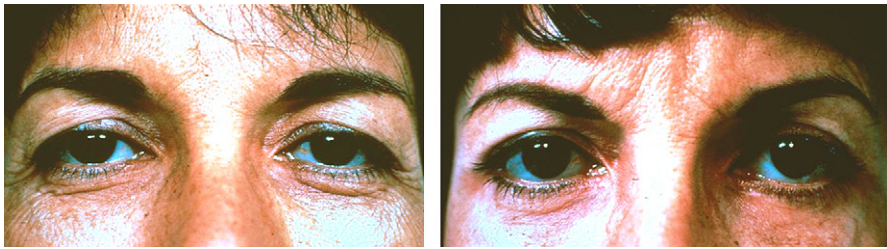


Fig. 2. A 53-year-old woman on whom the senior author performed a traditional blepharoplasty in 1969 shown before and 6 months after surgery. Note the brow drop, scleral show, rounding of the eyes, and frown exaggeration.

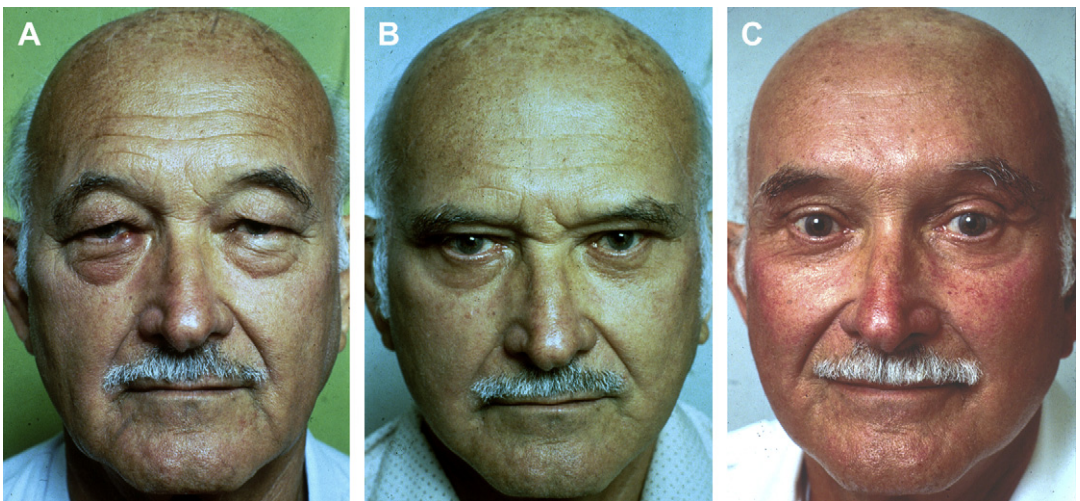


Fig. 3. A 60-year-old man shown (A) before and (B) 3 months after four-lid blepharoplasty with canthopexies into the bone. He declined recommendations for a simultaneous coronal lift. Note the profound brow drop and frown accentuation resulting from blepharoplasty without brow lift and corrugator muscle resection. (C) Same man 1 year after coronal lift with removal of corrugator frown muscle.

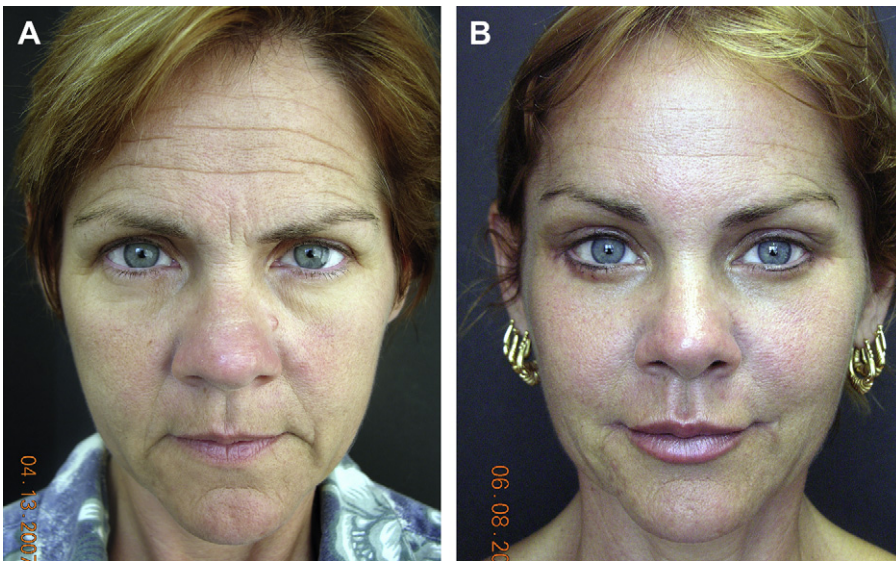


Fig. 4. Patient shown (A) before any surgery and (B) 6 months after Mag 5. (Coronal lift with corrugator resection, taking advantage of generous access for layered canthopexy into bone, lower blepharoplasty, and mid-cheek lift.) No resurfacing and no facelift was done.

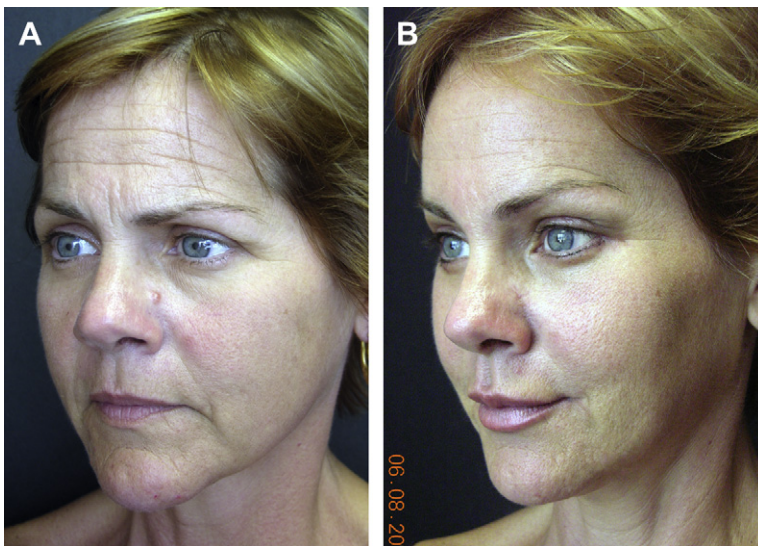

Fig. 5. Same patient shown in Fig. 4 (A) before and (B) 6 months after Mag 5. No facelift and no resurfacing.

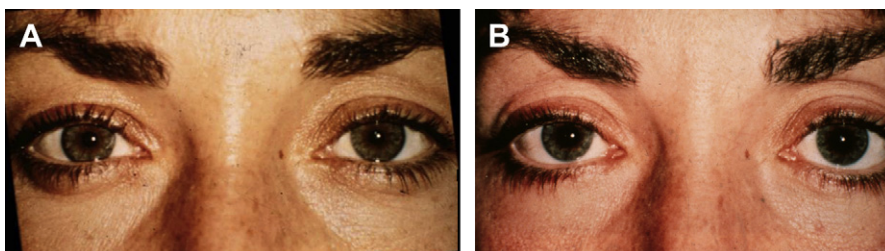


Fig. 6. A 26-year-old woman shown (A) before and (B) 1 year after lower lid surgery done elsewhere. Note the deforming character of lower lid blepharoplasty without a quality supporting canthopexy.

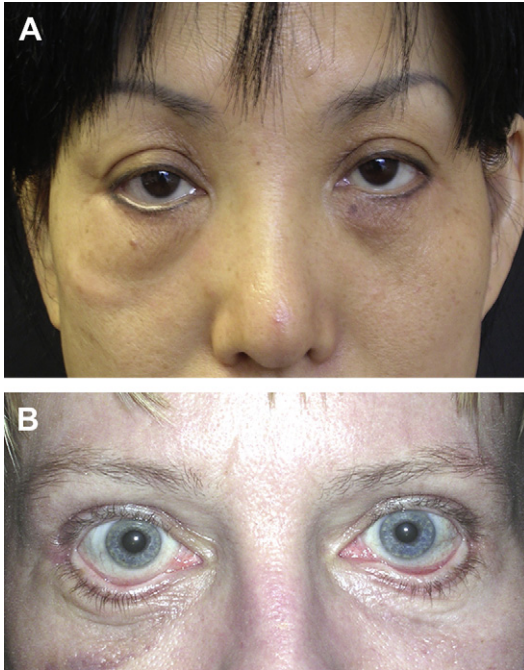


Fig. 7. (A) More exaggerated deformity with lower blepharoplasty and multiple attempts to correct (operated on elsewhere). (B) Patient referred for ectropion correction after lower blepharoplasty and attempted repairs. Periosteal canthopexy had been part of her third attempt at correction (unsuccessfully).

an extended canthopexy, which is essential in achieving a lasting and quality result from canthopexy, lower lid and midcheek elevation, and tightening as shown in **Fig. 5**. No facelift and no resurfacing were done to this lady.

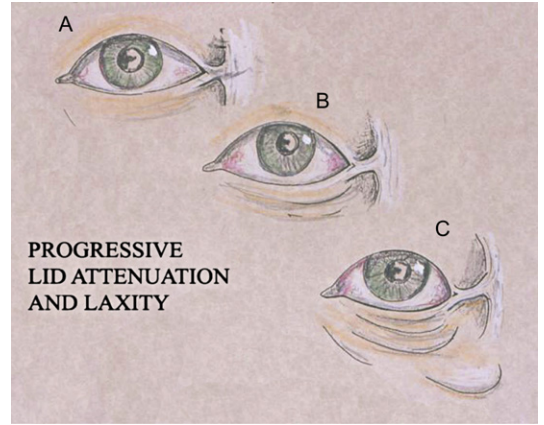


Fig. 8. (A) Typical female eye in the late 20s. Note the progressive change with age in (B) and (C) and the progressive change in shape with support attenuation.

The second epiphany was about the lower lid, where traditional tissue reduction, even trans-conjunctival fat removal, pinch excisions, and lid resurfacing surreptitiously deform, negatively changing the shape of the eyes as shown in the woman in **Fig. 6** before and after lower lid blepharoplasty. The patient in **Fig. 7A** has even greater deformity after multiple traditional lower lid procedures, and the “after” photograph of the patient shown in **Fig. 7B** is much worse because of the failure to address the essential pathology of the lower lids, that is, progressive lid and reticular laxity and atonicity¹⁶ as shown in the senior author’s drawing in **Fig. 8**.

It became crystal clear that the solution to lower lid shape “bagginess” and posture was a secure (meaning “into-the-bone”) canthopexy (**Fig. 9**),¹⁷

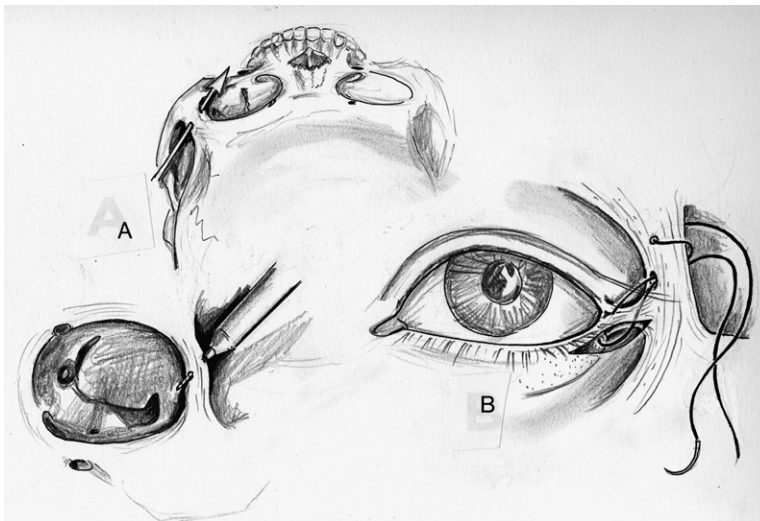


Fig. 9. Secure into-the-bone canthopexy. (A) Note tangential direction of drill hole. (B) Drill exits medial aspect of anterior orbital rim. Lateral canthal tendon and reticular tissue pulled into the drill hole with 3-0 Monocryl suture. Suture limbs separated and ligated with assistance of a second drill hole, usually placed above the main canthopexy tunnel.

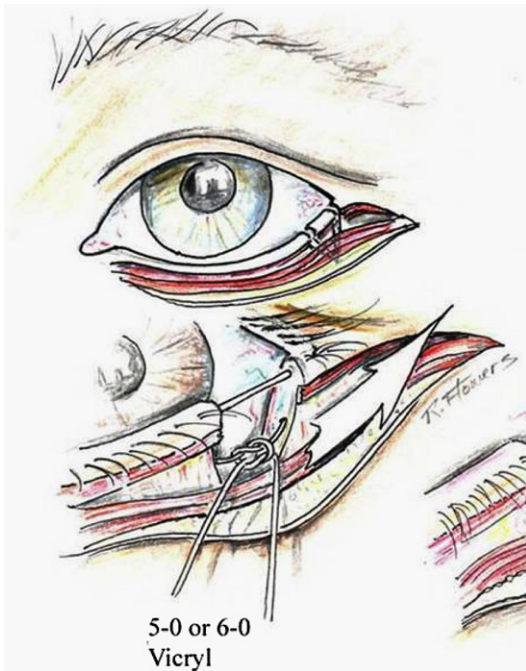


Fig. 10. Senior author's illustration of his technique for lid shortening, excising a triangular section of the deep lamella just before the tarsus ends near the lateral canthus.

with an accompanying lid length shortening of the deep lamellae when appropriate (**Fig. 10**), removing skin, muscle, or fat only when truly excessive. Not long after discovering the effectiveness of into-the-bone canthopexy, a second layer of support using the orbicularis muscle (**Fig. 11**) became a routine addition to canthopexy.

Here's the crucial question: Do these techniques make a real difference, and do they justify the additional time, effort, and expense? For us and our

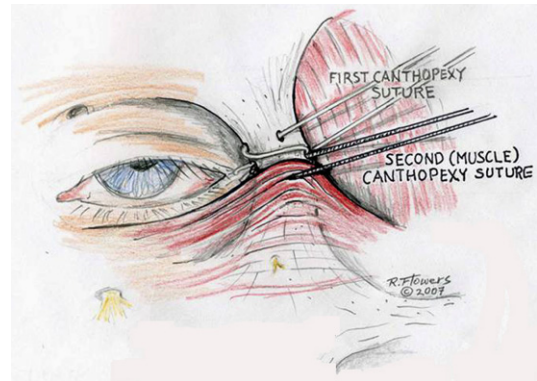


Fig. 11. Not long after initiating the into-the-bone canthopexy, a second layer of orbicularis support was added.

patients the answer is a clear-cut yes! But don't "trash" canthopexies into periosteum, for they do indeed offer meaningful, although typically only temporary, support (tarsal strap release and the second layer of orbicularis support both help prolong their effectiveness). With periosteal canthopexies, there is little need to worry about long-term "crowding" because these "lifts" rarely attain permanency. In contrast, the multilayered, into-the-bone canthopexies (**Figs. 12** and **13**) we describe herein are still secure, maintaining shape and posture 20 and 30 years later.

The magic of an enduring canthopexy is the layered repair.¹⁸ First, the tendon and retinaculum are pulled into a drill hole^{16,19,20} exiting at the anteromedial aspect of the orbital rim (**Fig. 12B**), with a second layer repair of orbicularis or, better yet, a second layer of orbicularis, skin, subcutaneous tissue, orbital septum, and the entire caudally released periosteum all included in the second

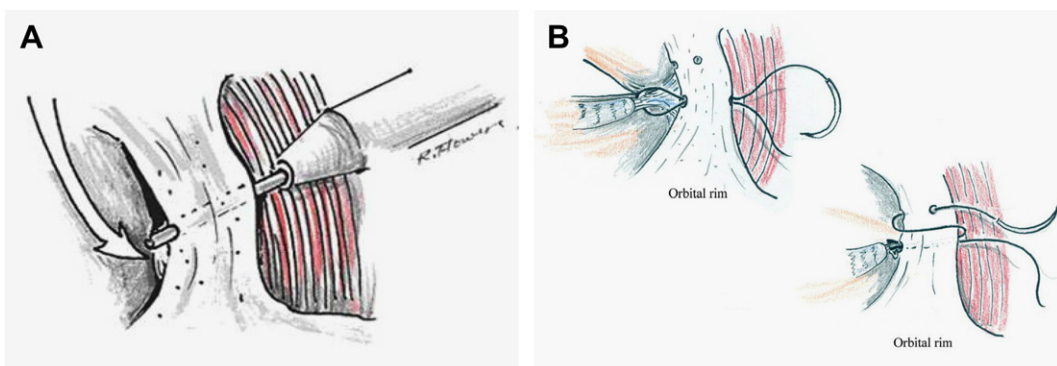


Fig. 12. (A) The drill hole must exit at the anteromedial aspect of the orbital rim. (B) Suture grasps tarsal tendon retinaculum junction and sometimes a little tarsus. Second drill hole facilitates suture separations for ligation (burying the knots within the drill hole).

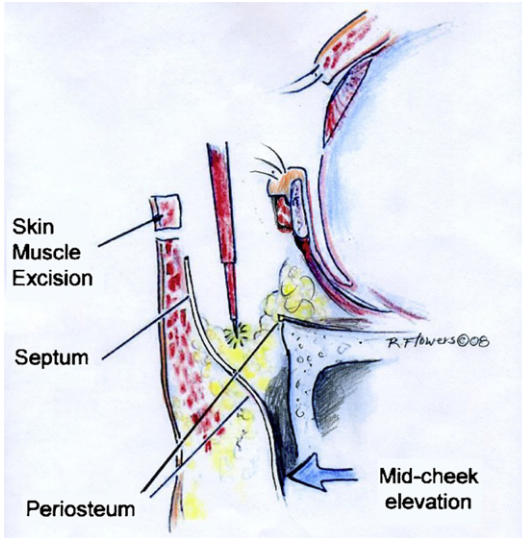


Fig. 13. Most of the time, our “orbicularis” flap actually includes skin, subcutaneous tissue, orbital septum, and the entire caudally released periosteum.

layer repair. This offers an even more impressive long-term correction (**Fig. 13**).

The third epiphany dealt with deep repair. The goal of half of the people seeking lower lid surgery was, and remains, correction of the deep grooves in the lower lid and the lid-cheek junction areas (**Fig. 14**). These deformities until recently were being addressed by only a few surgeons.²¹ At first, solving these defects meant fat grafts and fat transpositions and even subgaleal tissue grafts.^{22–24} Loeb,^{25–27} also during the early 1970s and in the Southern Hemisphere, was using similar techniques. During this same period, the senior author began carving and perfecting the first tear trough and “comprehensive” malar implants (**Fig. 15**). They worked splendidly for years, leaving him with an impression that only implants (combined with canthopexy) could give the desired correction for such deformities (**Fig. 16**) until the inevitable occurred, and the three epiphanies coalesced.

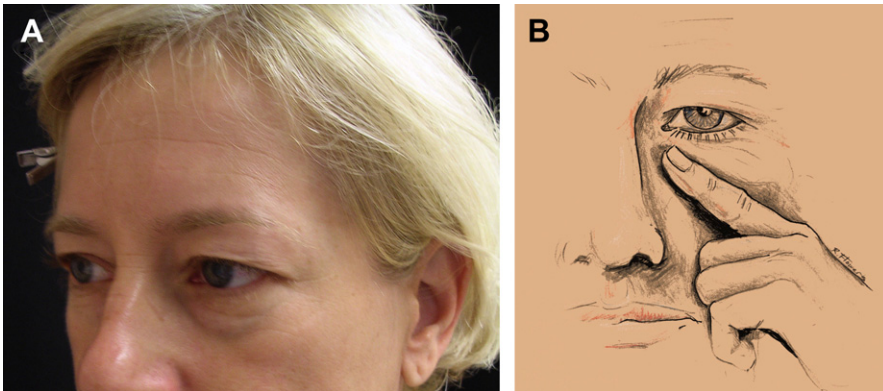


Fig. 14. (A) Patient with deep suborbital malar bony groove deformity (tear trough deformities) (see **Fig. 57** for before and after photographs). (B) True tear trough deformity accompanies a palpable groove easily defined by the side of the index finger.

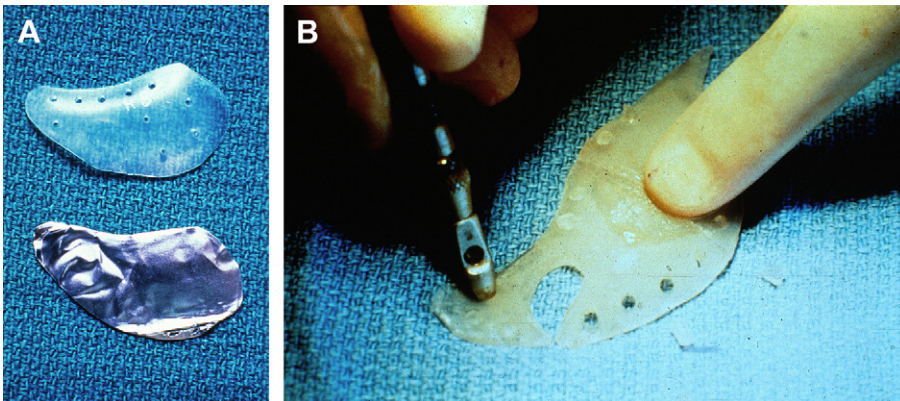


Fig. 15. (A) Tear trough implants. A tear trough implant with suture pack foil template was made in the operating room to help locate the nerve “cut-out.” (B) Comprehensive malar implants (custom fabricated) include both malar and tear trough components.

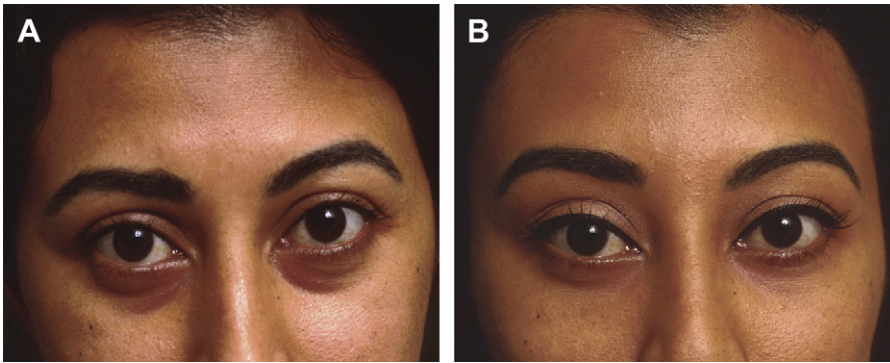


Fig. 16. A 36-year-old woman (A) before and (B) 1 year after tear trough implants with limited periosteal elevation.

Here's what happened. The cornerstone of upper lid repair became the coronal lift¹⁹ with corrugator resection; for the lower lid, it became a layered canthopexy into the bone; and for suborbital malar groove correction (true tear trough deformity) (Fig. 17), it became (for two decades) the tear trough implant, usually combined with canthopexy and typically performed with a coronal lift. But here is what happened as they "coalesced." Placing tear trough implants (as well as malar implants) required releasing and raising the periosteum from the orbital rim and malar bone (Fig. 18). This implant-placing release of periosteum naturally demonstrated the ease of complete malar and zygomatic subperiosteal elevation and release, disconnecting the deep lid connections from the arcus marginalis as shown in Figs. 13 and Fig. 18B. This disconnection severs the muscle's adherence to periosteum at the orbital rim, thereby eliminating that sharp depression which delineates lower lid from cheek skin (the nasojugal groove).

This release naturally led to the extended second layer of the canthopexy support just described, containing the entire periosteum and everything superficial to it, with a 3-0 Vicryl suture securing the malar tuft periosteum and fibrous tissue to the orbital rim (Fig. 19). This extended support accomplishes an awesome correction and lasting canthopexy and midcheek lift as shown in the 3-year follow-up photograph (Fig. 20) of the blepharoplasty complication shown earlier (see Fig. 7A) and the preoperative photograph (Fig. 21A) of a 57-year-old woman with 30 years of Crohn's disease treatment shown 1.5 years later (Fig. 21B).

The three epiphanies coalesced with five surgical components joined into one operation that came to be called the "Mag-5," that is:

- A lateral emphasis frontal lift with
- Corrugator resection
- Lower blepharoplasty
- Extended layered canthopexy into bone

- Midcheek lift with subperiosteal malar release with an absorbable suture securing the malar tuft periosteum and fibrous tissue to the orbital rim (see Fig. 19).

As the operation "morphed" from the "coronocanthopexy" of the late 1970s to the more extensive lift performed today, the name also "morphed" to "Mag-5" (short for MAGnificent 5), representing its five component parts and the way our nurses felt about the operation. Contrary to the names the senior author had proposed, such as "corono-canthopexy," "cantho-maximoplasty," or "cantho-optimaplasty," the designation of Mag-5 "took." The nurses loved it, the




Fig. 17. Illustration of the three cornerstones of periorbital repair coalescing into one magnificent operation, the Mag-5.

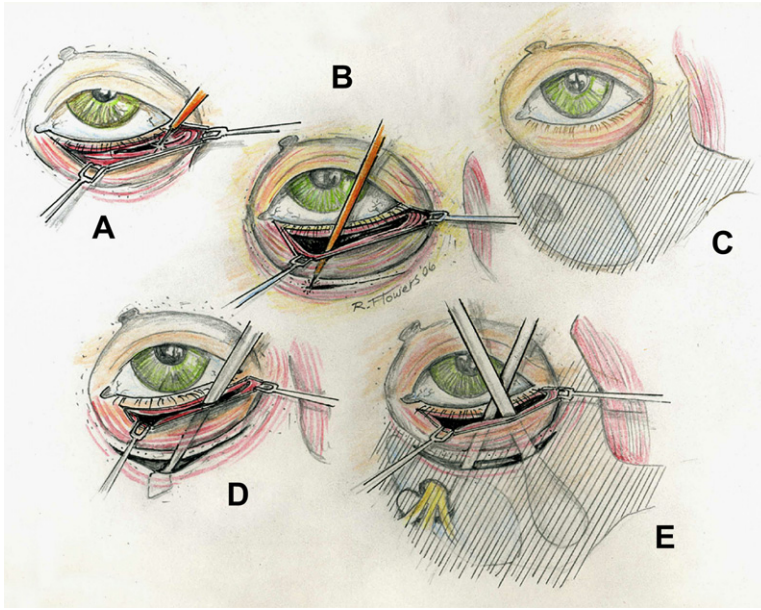


Fig. 18. (A) Elevating a skin-muscle flap (including orbital septum). (B) Continuing the flap elevation by releasing the arcus marginalis connection to periosteum. (C) Showing maximum desirable extent of periosteal elevation, with optimal position of tear trough implant when, and if, indicated. (D) Initiating periosteal elevation with large Cottle dissector. (E) Completing the periosteal elevation with a medium-sized periosteal elevator and disconnecting it from the bone caudally.

media liked it, and, best of all, the patients liked it because it was easy to remember and easy to say. As surgeons, we take pleasure in the way it flows in our patient's and prospective patient's speech.

For us, the Mag-5 is the premiere rejuvenating and restorative operation in esthetic surgery. It can be *transformative* as well but only when, and if, *transformation* is the desired goal.

Fig. 22 shows a 42-year-old woman who underwent the Mag-5, and **Fig. 23** shows a 63-year-old woman before and 6 months after a similar operation. This combined operation (Mag-5) becomes a powerful midcheek lift that:

- Lifts the globe
- Sucks in and then restrains the lower orbital fat
- Helps fill in upper orbital hollows
- Eradicates nasojugal grooves
- Covers up mild-to-moderate tear trough groove deformities without the need for implants or filler
- Lifts lower cheek sag
- Eliminates most lid and cheek wrinkles
- Enhances malar fullness
- Eliminates malar fat pads and festoons
- Lifts the corner of the mouth slightly
- Beautifully corrects the upper face

Understand however, that the Mag 5 demands an effective lateral brow-temple lift. The danger of the Mag-5 operation is its effectiveness and ease of overcorrection, resulting in significant tissue crowding in the upper cheek, lateral brow,

and temple areas unless these areas themselves are securely lifted.

The awesome Mag-5 operation relegates upper blepharoplasty, even East Asian lid surgeries, and the senior author's own tear trough implants – as well as typical facelifts in general to accessory roles in facial rejuvenation, which may or may not accompany the frontal lift and/or Mag-5.

Endoscopic and other effective lateral lifts, such as Knize-type procedures, and direct excision juxtabrow-temple lifts (**Figs. 24** and **25**) can substitute for coronal lifts when and if necessary, especially in persons who have undergone

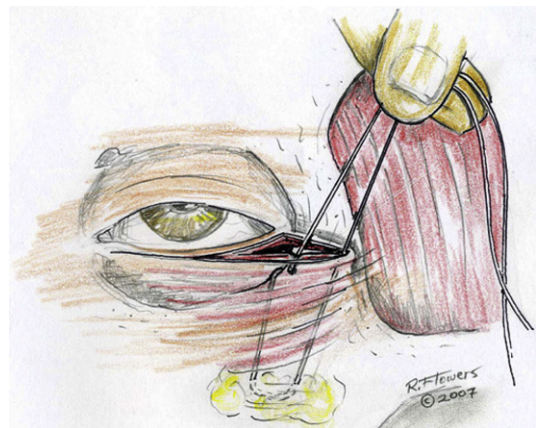


Fig. 19. Midcheek lift supporting suture with 3-0 Vicryl connecting the malar tuft and fibrofatty tissue to a drill hole in the lower lateral orbital rim.

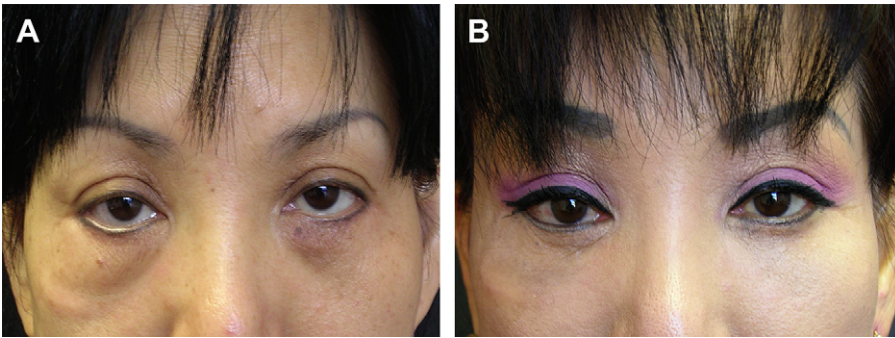


Fig. 20. Same patient shown in Fig. 7A. (A) A 53-year-old Asian woman with previous blepharoplasties resulting in upper lid ptosis and lower lid and canthal dystopia referred for correction. (B) Three years after Mag-5, which included canthopexy into the bone and a second-layered canthopexy support of the entire periosteum and everything superficial to it, with a 3-0 Vicryl suture securing the malar tuft and fibrous tissue to the orbital rim (see Fig. 19).

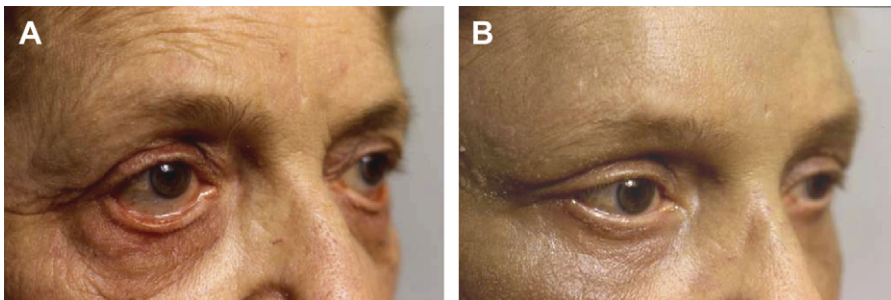


Fig. 21. A 57-year-old woman with 30 years of Crohn's disease treatment (A) before and (B) 15 months after Mag-5 with lower lid shortening.

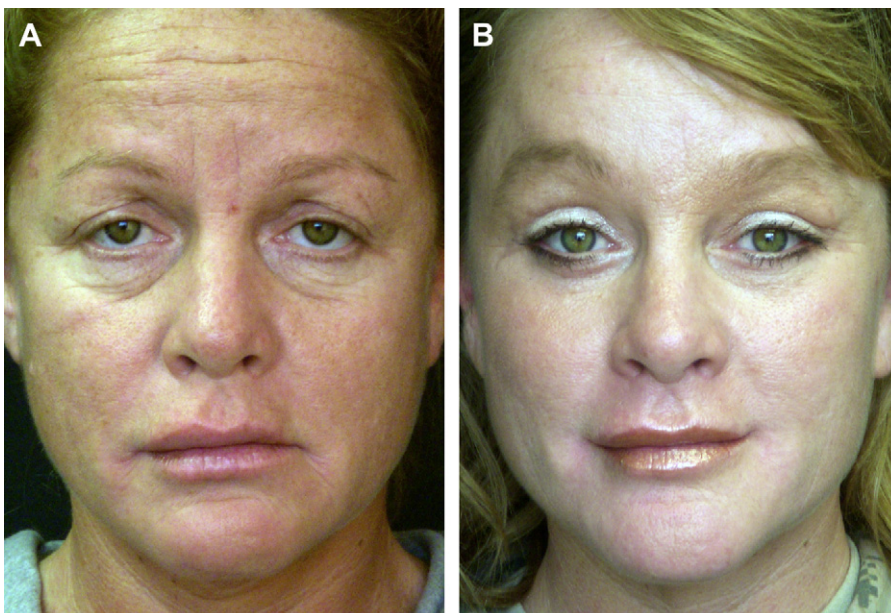

Fig. 22. A 42-year-old woman (A) before and (B) after Mag-5 with shortening of the lower lids and Valentine anguloplasty 2 months postoperatively. (Her skin lightened by staying out of direct sunlight.)

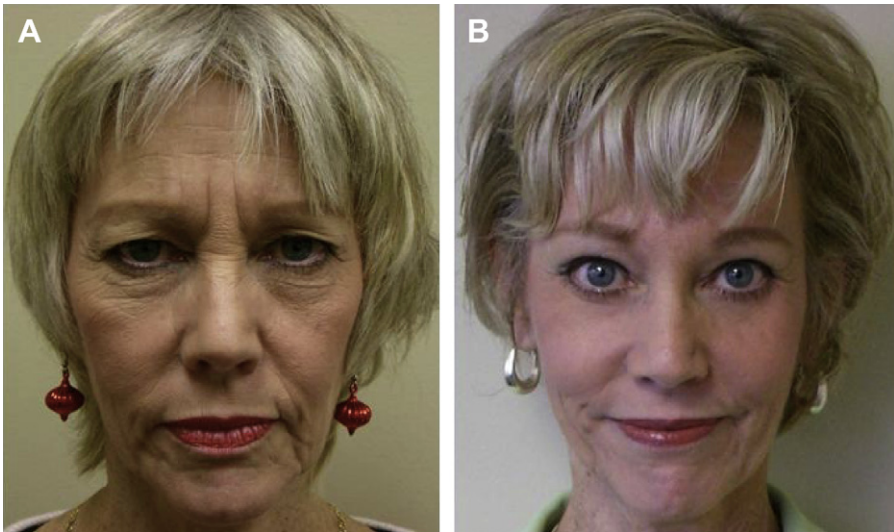

Fig. 23. A 63-year-old woman (A) preoperatively with no history of previous surgery and (B) 6 months after Mag-5 and upper lid blepharoplasty. The operation was performed by the junior author (AC).

extensive hair transplants or other scalp surgeries in whom deep scarring will likely limit the effectiveness of the lift (or possibly compromise its blood supply) (Fig. 26). But their use requires that the into-bone, multilayered canthopexies be done through subcanthal incisions. In these situations, the second drill hole (for suture separation) is best placed caudal to the main canthopexy tunnel (Fig. 27). Some may prefer to access the orbital rim through the lateral aspect of an upper blepharoplasty incision; however, after mastering the approach described herein, other surgeons, like the authors, are likely to find a marked decrease in indications for upper lid surgery.

It is prudent to keep as a failsafe or backup reserve, a lateral juxtabrow-temple lift for the occasional patient in whom the lateral coronal, endoscopic, or other type of lift fails to adequately uncrowd the lateral brow and temple region (Figs. 24, 25, 26, and 28).

SURGICAL TECHNIQUE

Before scheduling surgery it is crucial to assess the patient while in a vertical position, mapping out the orbital region,¹⁵ including the lower and upper lids, and the amount of skin, muscle, and fat (if any) to be removed and from which areas (Fig. 29). On the map, also note whether there is asymmetry in brow location (usually, one is lower than the other). Note lid tone and aperture shape and whether there is vertical dystopia or scleral “show” as well as your judgement on the need for lower lid shortening. Check out whether there is lid ptosis on either side and whether it

disappears when the brow is raised, or if it is discovered only by raising the brow. Look for lid retraction, both the obvious and that hidden by brow ptosis or droopy eyelids. Examine the eyelids for scars suggesting previous lid surgery. Measure the amount of lid skin between the lower border of the central eyebrow and the lash line on both sides. Determine whether, and how much, brow elevation is needed to keep each lid from closing. Look for globe prominence and the symmetry

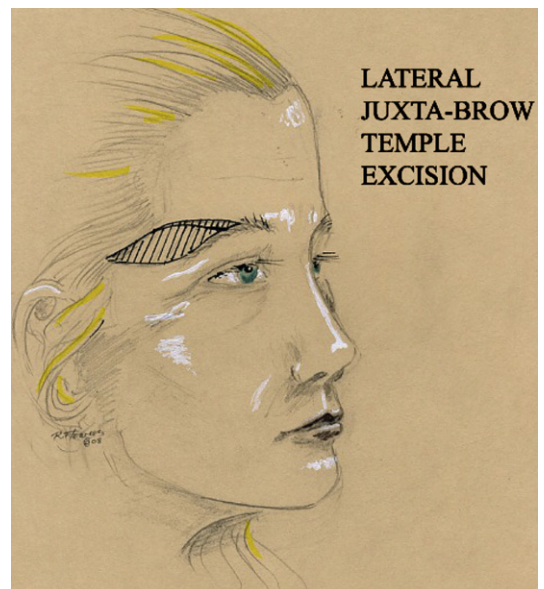


Fig. 24. Lateral juxtabrow-temple excision used in Figs. 25–28.

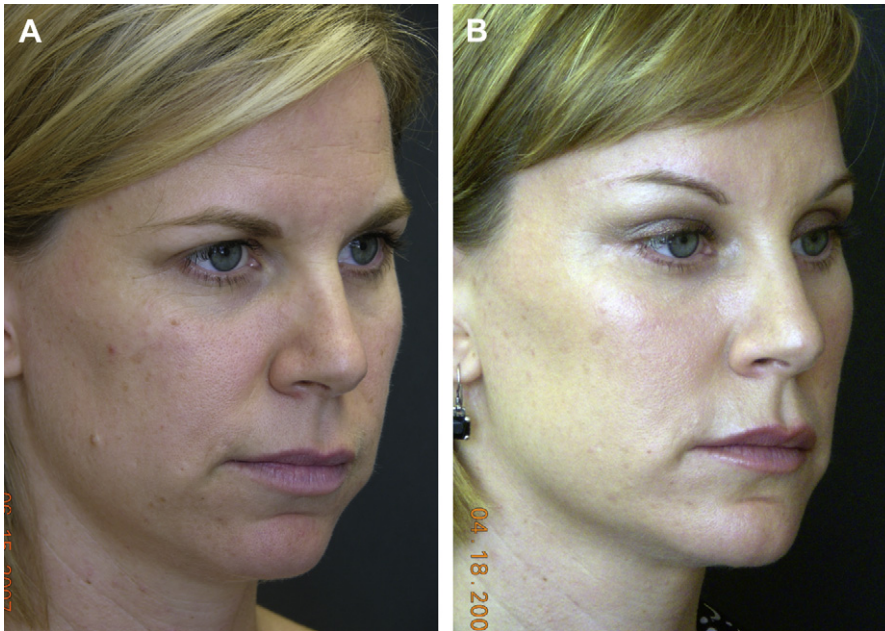

Fig. 25. A 37-year-old woman with profound asymmetric right brow ptosis shown (A) preoperatively and (B) 1 year after Mag-5 and chin augmentation. We elected a right juxtabrow-temple excision “boost” 2 weeks postoperatively to correct the persisting asymmetry. Note the absence of visible scar.

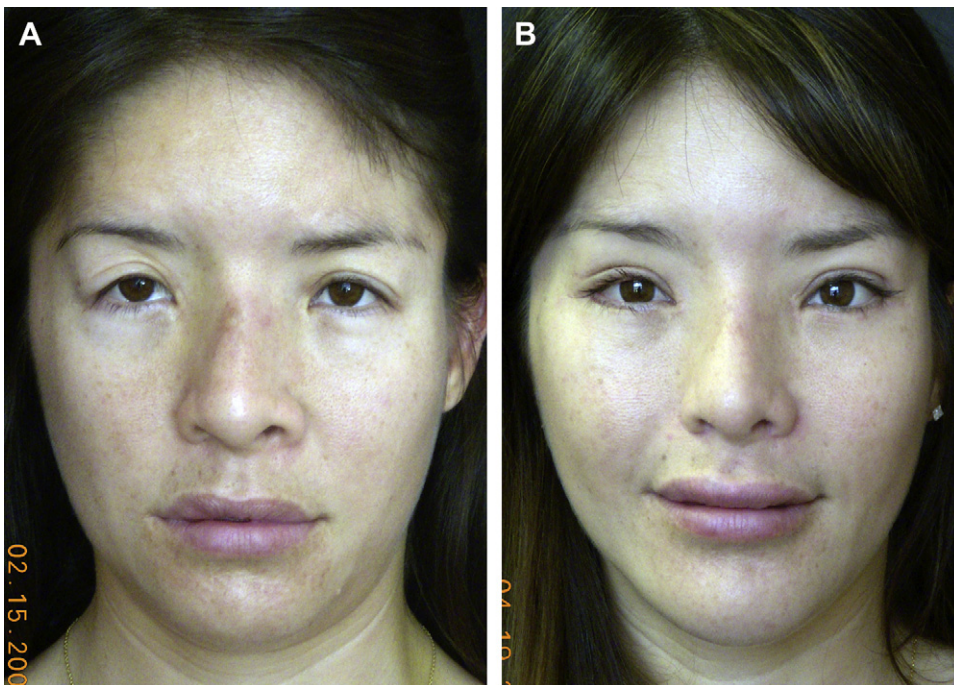


Fig. 26. (A) A 30-year-old woman with a history of congenital cranial synostosis, orbital dystopia, and multiple other facial deformities including severe asymmetry. She had undergone multiple operations in quest of periorbital “transformation” rather than “restoration”. (B) Juxtabrow-temple lifts were chosen over other forehead lifts because of extensive scalp scarring and the likelihood of inadequate lateral brow and temple elevation to accommodate the profound Mag-5 lift and potential excess in that area. Her Asian lid surgery was also redone.

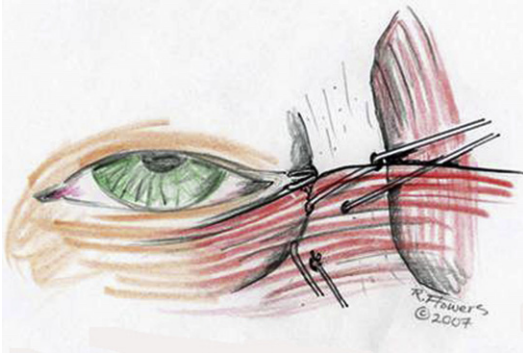


Fig. 27. The drill hole for suture separation (allowing ligation) is best made below rather than above the key drill hole when the entire canthopexy is done through a subcanthal incision.

thereof. Check the globe's relationship to both the superior and inferior orbital rims for true exophthalmos, "hemi-exophthalmos" or "negative vector" relationships. Perhaps most important of all is to check for Bell's phenomenon, that is, whether the globe rotates upward (protecting the cornea) when the eyes are closed. Note frown characteristics and any need for orbital rim reduction.

Mark the incisions, the planned excisions, and then, with the patient supine, delineate with a skin marking pen the extent of the bony malar complex (for undermining). Also, delineate the location of the infraorbital foramen (and nerve).

After appropriate preparation, start the surgery by making the lateral subcanthal incision which extends a short distance beyond the eye (**Fig. 30**), taking care in this area to cauterize as necessary while cutting. A Colorado needle on blended current is ideal for incising through the orbicularis and down to the periosteum. Cauterize as needed but sparingly. Continue the dissection subperiosteally in both caudal and cranial directions to mobilize the orbicularis flap. The extended flap mobilization includes widely releasing the orbicularis and orbital septum from the arcus marginalis (see **Fig. 13**). Then carefully and precisely elevate the entire malar periosteum lateral, inferior, and cephalad to the infraorbital nerve, including the malar eminence and midcheek tissue overlying the juxtaposed two thirds of the zygomatic arch (see **Fig. 18E**), so that the whole cheek complex moves upward with the two-layered canthopexy and midcheek support suture. Our favorite dissection devices are a large Cottle dissector and a medium-broad periosteal elevator. (Often, we

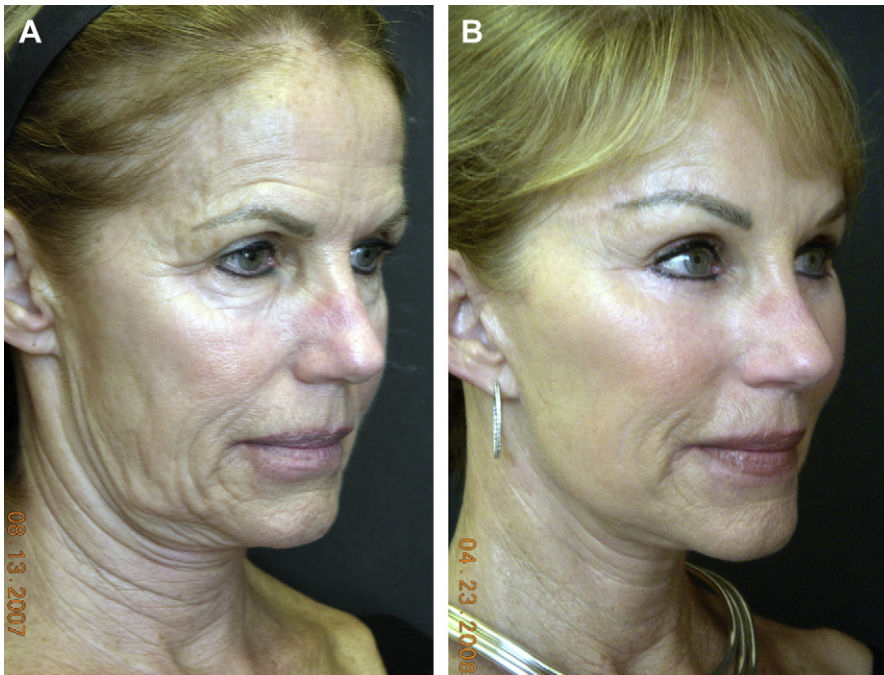

Fig. 28. A 60-year-old woman shown (A) before and (B) 1 year after Mag-5 and a subsequent bilateral juxtabrow-temple lift "boost" 10 days postoperatively to correct the minor degree of crowding caused by the excessive effectiveness of the Mag-5 canthopexy midcheek lift. Note the barely detectable scar.

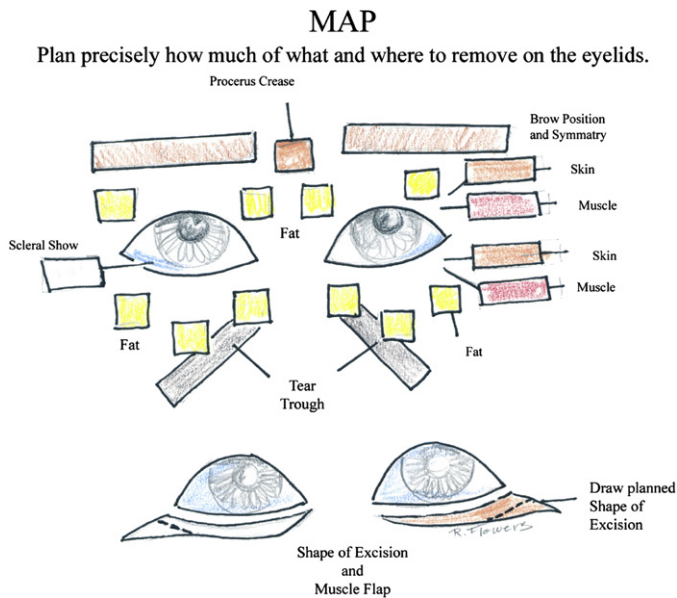


Fig. 29. A map is made with the patient positioned vertically before you. All pertinent features are designated, including tissue to be removed (if any), the position and symmetry of the brows, the presence of ptosis, the prominence of globes, and other pertinent features.

choose to raise the periosteum medial to the infraorbital nerve as well, taking great care to avoid injury to the nerve and the accompanying vessels). Try to preserve the zygomatico-facial nerve and its companion vessels during the dissection (Often, there are two nerves on each side). Secure the midcheek periosteum and malar fibrous tissue through a drill hole made on the inferolateral orbital rim with an absorbable suture of the surgeon's choice (see **Fig. 19**). The authors prefer a 3-0 Vicryl (Ethicon) suture. A medial aspect of the orbital rim drill hole for the malar periosteum and tuft fixation is preferable to a lateral aspect of the rim, which invades a vascular area (**Fig. 31**), but both provide excellent malar support. Ensure that the tissue purchase of the malar suture is deep enough beneath the dermis to minimize submalar dimpling postoperatively. Easy testing can be performed after suture placement by a light tug on the malar tuft (or "midcheek lift") suture (**Fig. 32**). After ligating the suture, bury the knot within the drill hole with a fine mosquito hemostat whose ridges have been filed smooth. We usually squirt a small amount of antibiotic solution into this as well as all of the other drill holes after burying the sutures within the holes. Delay ligating the malar tuft suture until all gauze packing is out of the cheek and preferably until just before the orbicularis layer of the double canthopexy is ligated into position. If there is persisting oozing, place a butterfly drain, allowing it to enter through a tiny incision in the alar crease, grasping the beveled end of the butterfly tube with a fine-tipped mosquito clamp (**Fig. 33**).

At any point after the midcheek elevation is complete, we may make the subciliary incisions, pushing the separated iris scissor blades across the subciliary lid and incising and excising skin and muscle separately or together. It is easier to judge the amount of excess skin and muscle tissue in the lower eyelid after the midcheek anchor suture is securely ligated. With the muscle under tension, raise the skin off the muscle approximately 2 mm more than the amount anticipated for skin excision. If no lid skin removal is in the plan, subciliary incisions are unnecessary.

Be sure to leave the pretarsal orbicularis undisturbed. Below that, divide the orbicularis with scissors (cutting cautery may cause lash

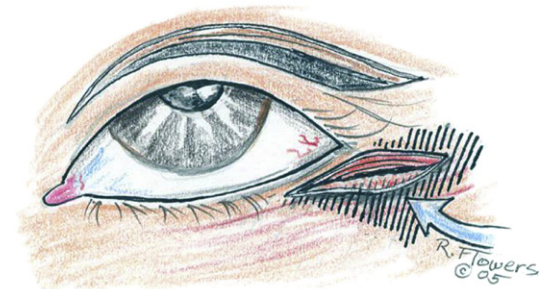


Fig. 30. A subcanthal subciliary incision is made down through the orbicularis, extending a short distance beyond the lateral canthus. The skin is undermined in the cross-hatched area or even more widely, especially around the end of the incision.

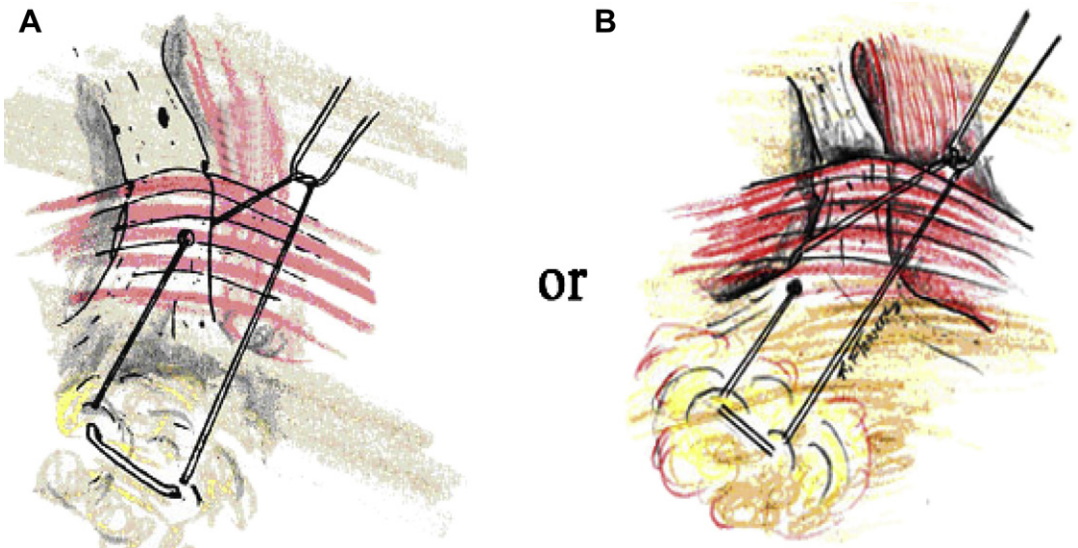


Fig. 31. Midcheek lift enhancing malar tuft suture, attaching malar periosteum and fibrofatty tissue to an elevated position on the orbital rim. The drill hole provides a secure anchor to either (A) the lateral aspect of the orbital rim, which often causes oozing at the junction of the temporalis muscle to the orbital rim, or (B) preferably to the inferolateral aspect of the medial border of the lateral orbital rim, where oozing is unlikely to be a problem.

loss), preserving nerve and vessel bundles where possible. 3.6 power surgical operating loupes are extremely helpful for surgical precision. Be sure to retain a triangle of muscle laterally as depicted in **Fig. 34**, dissecting the skin off the muscle laterally and inferolaterally and carefully protecting the integrity of the muscle, which is an essential part of the second-layer canthopexy.

Before starting the canthopexy, remove the precise amount of fat, if any, designated as excess preoperatively, and release with a Colorado needle the downward directed, straplike reflection of the lateral canthal tendon with attachments to the tarsus, known as the tarsal strap,^{28–34} as depicted in **Fig. 35**. Several millimeters deep to the orbital rim and septum is where it inserts into

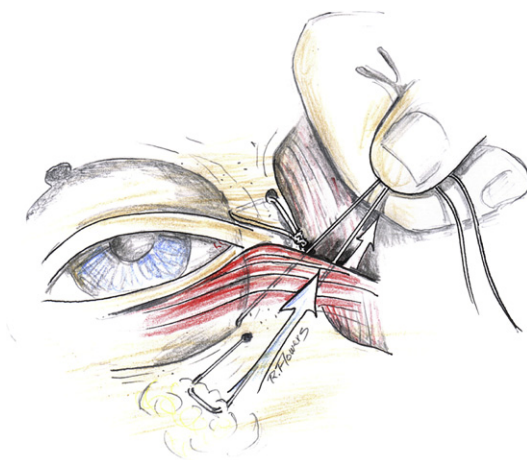


Fig. 32. Tug on the malar tuft suture before ligating to assess the depth of the suture beneath the dermis and the dimple created by traction. The suture should be deep enough to avoid dimpling but tight enough to cause a slight indentation.

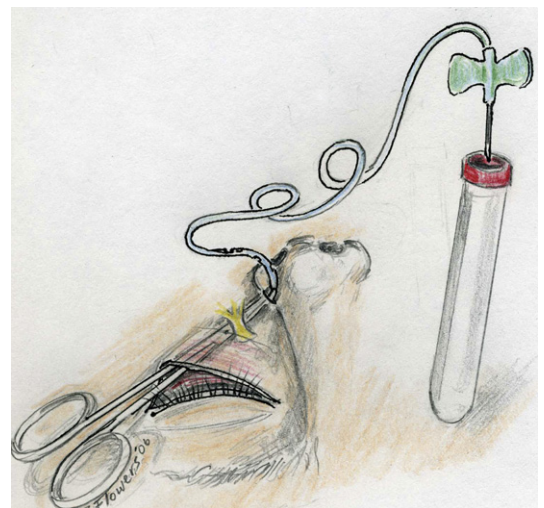
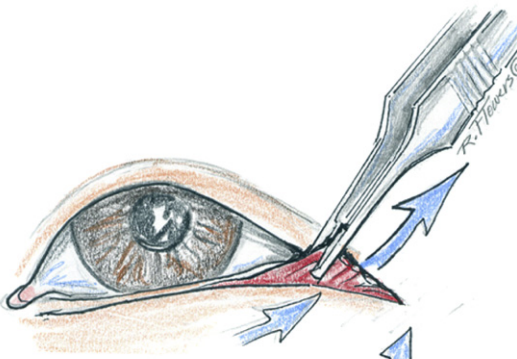


Fig. 33. If persisting oozing is a problem, a butterfly drain is placed through a tiny incision in the alar crease, grasping the beveled end of the tube with a fine-tipped mosquito clamp.



Undermined lateral flap for advancement and fixation

Fig. 34. A triangular segment of skin-denuded muscle is retained laterally to suspend to the orbital rim as the orbicularis flap. The muscle (preferably muscle and periosteum) should be widely undermined to accommodate the superior lateral lift.

the anterior but inferolateral orbital wall. This fibrous strap is distinct from, and inferior to, the lateral canthal tendon proper. Its release allows greater upward mobility of the lateral canthus, easing its permanent (or long lasting) restoration to its original youthful position or, if desired, successfully correcting a congenital or developmental transverse or anti-mongoloid intercanthal tilt. Usually, no elevation above the original insertion is required. It is not necessary to disinsert the main (and more superior) attachments of the lateral canthal tendon, except when exceptional elevation of the canthus is required, but reinsertion and tightening with aperture length restoration will give

the illusion of a greater tilt while, in fact, it just restores the natural youthful contour. It should appear overcorrected initially to end up with the most desirable appearance.

By 1½ weeks after surgery, the patient's appearance is no longer so exaggerated, but it takes 6 weeks to 2 months to relax to a comfortable level and 2 to 4 months to be "camera ready" for close-ups. Reinsertion of the lateral canthal tendon and connected retinacular tissues gives a profoundly secure canthal restoration when drawn into orbital rim drill holes and supported with a good second-layer repair of orbicularis and skin or, even better, periosteum, orbital septum, malar connective tissues, orbicularis muscle, and skin, plus the midcheek supporting orbital rim to malar tuft and periosteum suture (see **Figs. 13** and **19**). The end result is well worth the early inconvenience.

The next surgical step is to identify the desired point of canthal fixation on the lateral orbital rim. There are landmarks that aid in precisely locating the ideal point for canthopexy insertion into the bone; however, the canthopexy point is most precisely located by sliding a small metal ruler down the edge of the orbital rim bone (**Fig. 36**). The ruler will "catch and stop" at an angulation in the rim near the prominence of Whitehall's tubercle. This point accurately locates the optimal site for canthal attachment in 98% of the population. Mark that point with a marking pen. Raise the now mobile lateral canthus with a small forcep to the designated marked position (**Fig. 37**) and adjust the mark if necessary. Look at the tilt and allow slight exaggeration. Also, look at lid coverage of the lower limbus and iris on direct

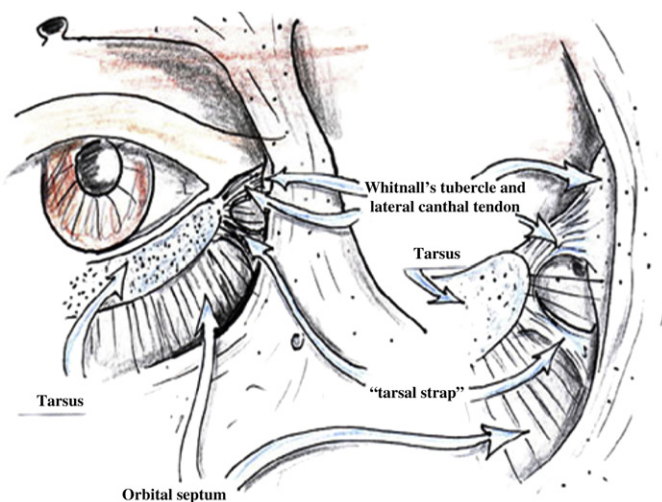


Fig. 35. Release of the dense tethering connective tissue attachments (tarsal strap) of the lateral tarsus to the lower lateral orbital rim allows easy upward mobility of the canthus without disconnecting the lateral canthal tendon (see **Fig. 52**).

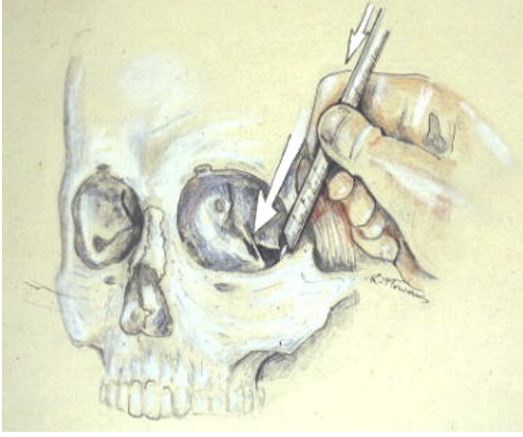

Fig. 36. The most consistent optimal point for the canthopexy drill hole exit is at the angulation on the orbital rim near the prominence of Whitnall's tubercle. This point is precisely located by sliding a metal ruler down the edge of the bone. It will catch and stop at the optimal point for the drill hole exit in the vast majority of patients, allowing one to mark the point.

forward gaze. The lid should cover 1.5 to 2 mm of iris, which will rise another 1 or 2 mm on direct forward gaze when the second layer of repair is added. Avoid doing canthopexies with the patient under general anesthesia if at all possible. It is very important for patients to open their eyes and look forward to give maximal accuracy to the canthal restoration and positioning and, of course, for maximal symmetry. Anticipate bizarre

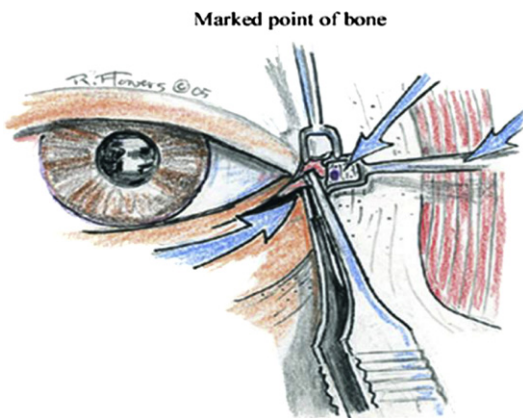


Fig. 37. The tendo-retinacular tissue of the lateral canthus is grasped and lifted to the proposed canthopexy point. The lid level and tilt are checked to ensure that the lid hugs the globe laterally (the drill hole must be on the slightly medial lateral aspect of the orbital rim). The lid should cover 1.5 to 2 mm of the lower iris at the completion of the operation and the same amount on each side.

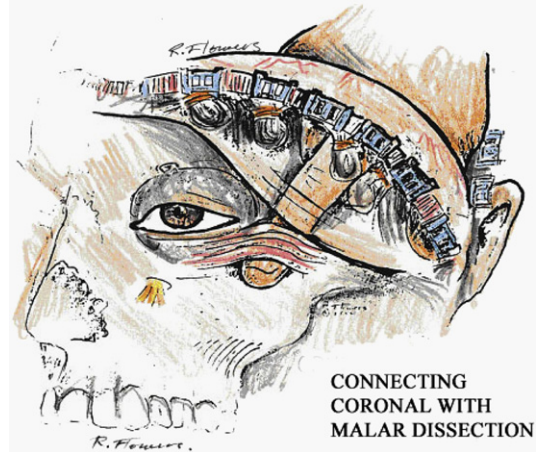


Fig. 38. Surgeon's finger demonstrating the connecting of the forehead flap–orbital rim area to the malar dissection.

rotation of the globe during general anesthesia, making accurate location of the canthus far less precise.

When combining the canthopexy with a coronal lift, raise the coronal flap, joining the forehead dissection with the malar and zygomatic dissection. Once a connecting tunnel is established, blunt dissection with the surgeon's thumb safely opens

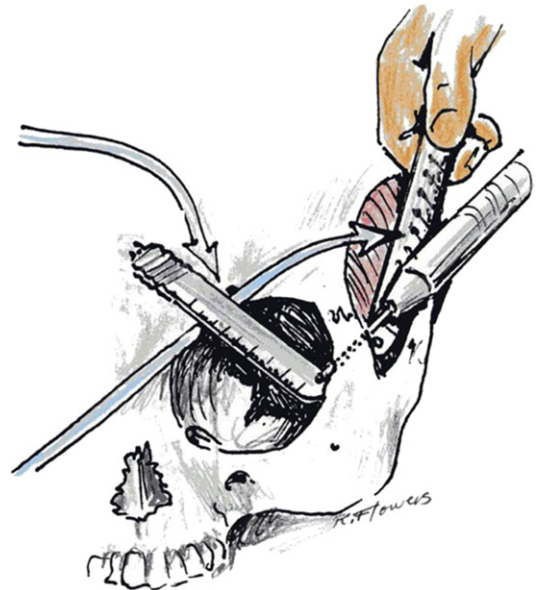


Fig. 39. Good scalp retraction with Clodius hooks combined with a flat metal ruler to depress the temporal fascia and muscle prevents injury and bleeding during the hole drilling for the canthopexy. A blunt instrument like the handle of a bladeless scalpel protects the globe.

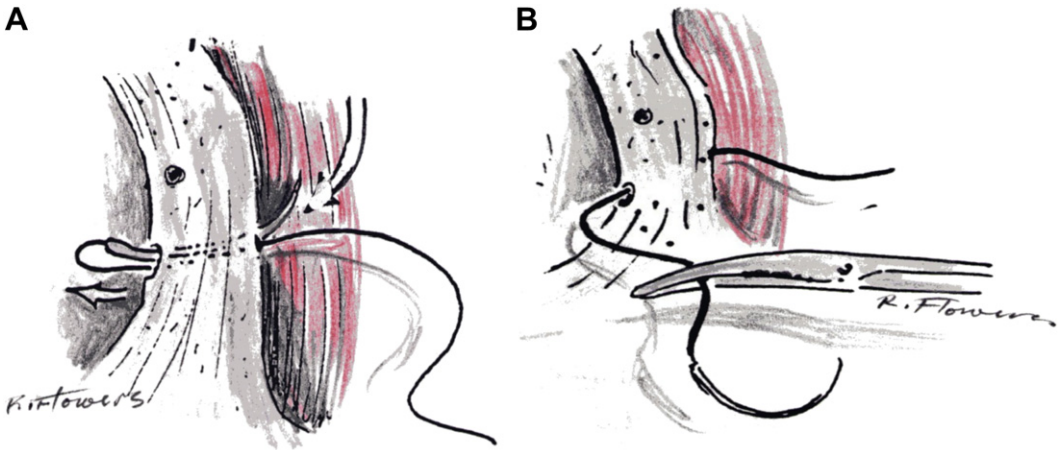


Fig. 40. (A) A 3-0 Monocryl suture is passed through the drill hole backward. (B) The suture is grasped with a smooth jaw instrument and the needle pulled through.

a generous communication between the two areas (**Fig. 38**). Careful Colorado needle dissection can be of additional help (see the details of upper face rejuvenation through coronal incision in our article in the preceding issue of *Clinics in Plastic Surgery*).³⁵ This generous channel between the coronal and subcanthal dissected areas allows comfortable access to the orbital rims to proceed with locating the proper canthopexy site and making the drill holes (see **Fig. 12B**).

We like to protect the temporalis muscle's attachment to the orbital rim during drilling with a metal ruler to prevent troublesome bleeding. The power drill bit enters the posterior bony rim tangentially and exits the medial aspect of the anterior orbital rim at the precise designated location. This is the "key" drill hole. A second drill hole a short distance cephalad allows separation of the two limbs of the key 3-0 Monocryl suture to facilitate ligation.

Good scalp retraction with Clodius hooks combined with a flat metal ruler to depress the temporal fascia and muscle provides the necessary protection to avoid injuring muscle while drilling a hole in the bone for canthopexy (**Fig. 39**). A blunt instrument like the handle of a bladeless scalpel protects the globe. After drilling, back a 3-0 Monocryl suture (on a tapered needle) through the principal canthopexy drill hole and grasp the suture with a smooth jaw instrument a short distance from the needle. A needle holder with filed jaws works great for doing this via the subcanthal, upper lid, or coronal incisions (**Fig. 40**).

Prior to placing the canthopexy suture into lid and canthal tissues, inject the lid beneath the lateral canthus with local anesthetic solution to

balloon out the conjunctiva (**Fig. 41**). The injecting needle should enter through the skin without penetrating the conjunctiva so that the fluid does not leak out. Now, take a good solid purchase of coalescing tissue including the inferior ramus of the lateral canthal tendon, retinacular connective tissue, and a small purchase of tarsus, if desired, with the tapered needle with 3-0 Monocryl (**Fig. 42**).

The level of the purchase of tissue should correspond to half the distance between the top and bottom of the tarsus. Test by pulling to ensure a good purchase of solid connective tissue. Too high a purchase results in entropion, too low

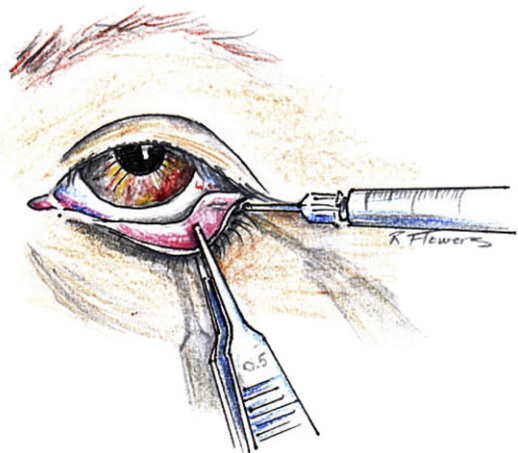


Fig. 41. "Balloon" the lower conjunctival fornix deep to the lateral lower lid and canthus with local anesthetic solution from a tuberculin syringe (1 mL) with a 30-gauge needle. The needle should enter the skin and not violate the conjunctiva (an opening in the conjunctiva allows the "balloon" to deflate).

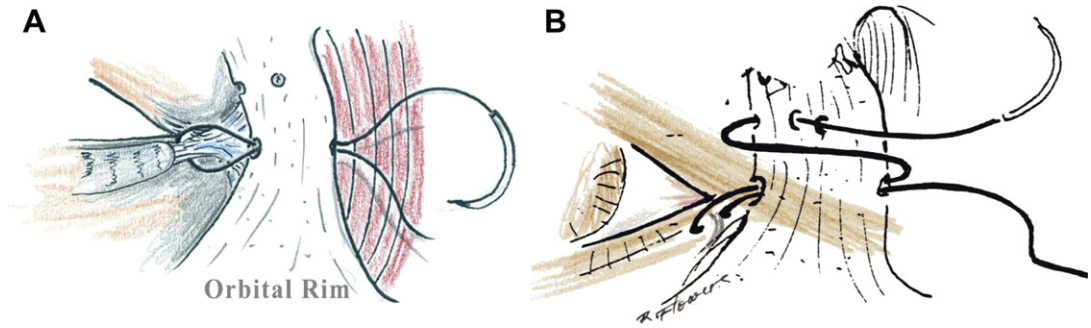


Fig. 42. One should take a good solid purchase of coalescing tissue consisting of inferior ramus of the lateral canthal tendon, retacular tissue (A), and a small purchase of lateral tarsus (B), if desired, using a tapered needle and 3-0 Monocryl suture.

a purchase causes lid margin eversion, and too far medial of a purchase deforms the lateral canthus. The ideal purchase is just medial to the lateral canthus.

After placing this key canthopexy suture, evert the lower lid to ensure the needle and suture did not transgress the conjunctiva. If it did, remove and replace the suture (Fig. 43).

Retrieve the canthopexy suture and ensure that the suture retrieval passes through the same channel traversed for suture placement in the coalescing lateral tarsus and canthal tendon. Back the canthopexy suture out through the same orbital rim hole it passed through earlier. Pass the needle back through the second orbital rim hole (medial to lateral) to separate the two arms of the suture (Fig. 44). Delay ligation of this key canthopexy suture until later. The key orbicularis suture, also of 3-0 Monocryl, secures the muscle flap to the orbital rim rather than into the orbital rim, as is the case with the “key” canthopexy suture. It takes advantage of the same drill hole used by the “main” or “key” into-the-bone canthopexy suture. When done via the coronal, the second key orbicularis suture is ligated immediately, burying the knot into the drill hole. Two to four additional sutures of

4-0 Vicryl follow, securing the orbicularis flap into the temporalis fascia via the scalp flap (Fig. 45). The “key” canthopexy suture ligation with knot burial within the upper drill hole is delayed until the skin and muscle excision and closure are complete and after placement of a temporary tarsorrhaphy suture (Fig. 46). Use one or two tarsorrhaphy sutures as seems appropriate. Ligation of the key canthopexy suture is postponed as long as possible because of the chemosis (conjunctival swelling) that accompanies its ligation, making lid skin closure and tarsorrhaphy extremely difficult. Make your task easier by postponing the key ligation as long as possible.

When the access for canthopexy is through a subciliary, subcanthal, or upper lid incision, drill

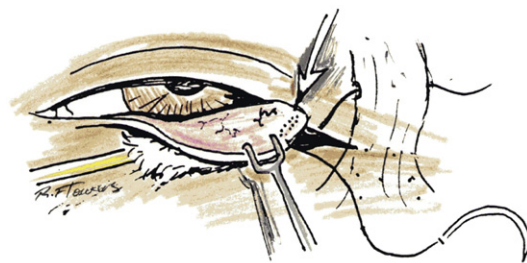


Fig. 43. The lower lid is everted to ensure that the canthopexy suture does not violate the conjunctiva. If it does, the suture should be removed and replaced.

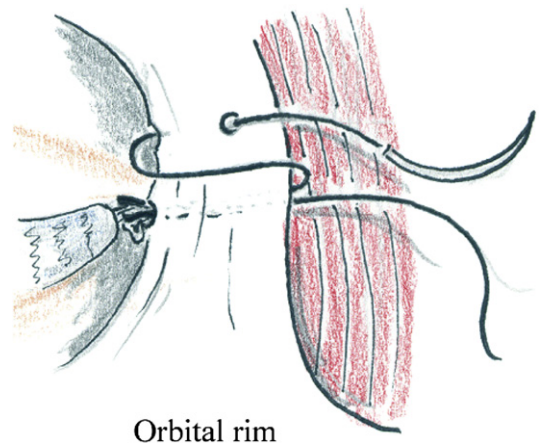


Fig. 44. The needle passed through the second orbital drill hole separates the two arms of suture to facilitate ligation. After ligation, poke the knot inside the drill hole.

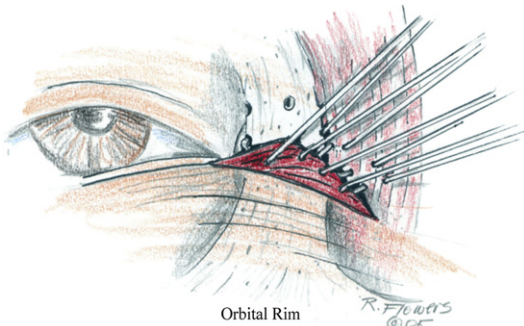


Fig. 45. Orbicularis flap being secured to orbital rim with monofilament suture through the main canthopexy tunnel. Three to four other sutures secure the lateral orbicularis flap to the temporalis fascia. (Usually done via coronal, but reasonably simple via other approaches).

hole creation is more difficult, requiring more creative retraction. Great care is necessary to avoid skin injury by the required tangential angulation (see **Fig. 12A**) of the drill and bit. When the key drill holes are made via a subcanthal incision, place the second drill hole (for suture separation and ligation) beneath or caudal to the canthopexy drill hole (see **Fig. 27**). This makes for greater ease in suture ligation. Place the muscle flap canthopexy sutures early, but delay their ligation until after

placement of two skin alignment sutures along the subcanthal and lateral lower lid incision. Because the canthopexy sutures distort skin alignment, and because both key sutures placed by subcanthal access require ligation before the skin can be closed, and because skin suturing will be more difficult because of the rapid onset of chemosis, these alignment sutures must be placed first. Pull the tails of the alignment sutures aside to allow ligation of the deeper canthopexy sutures without interference. Start by ligating the sutures connecting the lateral orbicularis muscle to temporalis fascia. Ligate the “key” orbicularis suture and the “key” canthopexy suture last among the deep sutures. Follow these by ligating the alignment sutures and then by closing the skin with 6-0 Prolene on a tapered needle. Bury the “key” suture knots within the drill holes, as done with other bone-anchored sutures.

Chemosis occurs immediately after ligation of the key canthopexy suture. For this reason, the prudent surgeon will place one or two tarsorrhaphy sutures prior to its ligation (**Fig. 46**). This facilitates a simple and quick tarsorrhaphy that is less time consuming than after chemosis develops. Remember that the above sequence is specifically for the lower lid or subcanthal placement of the canthopexy sutures.

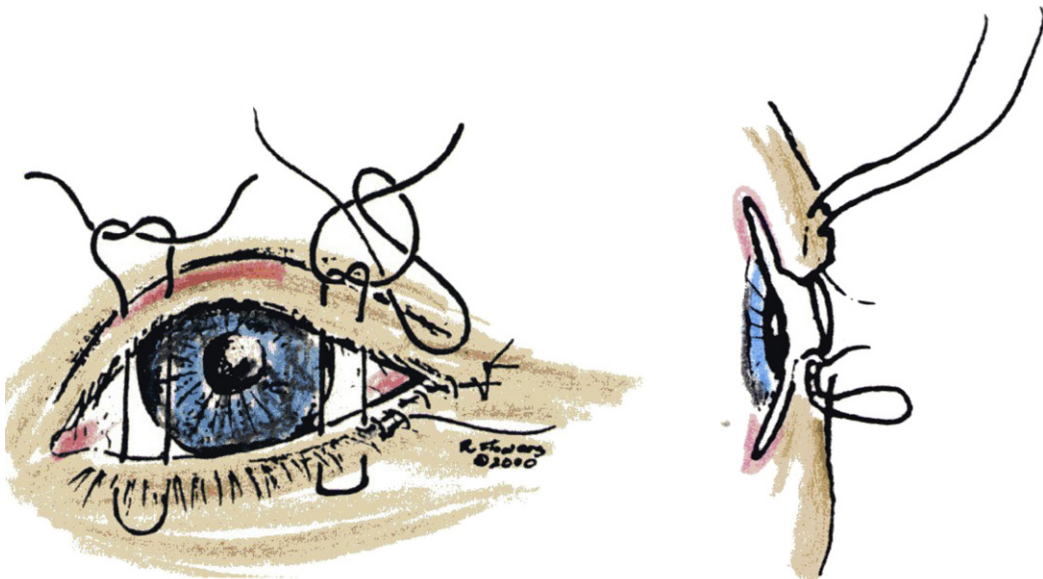


Fig. 46. Place temporary tarsorrhaphy sutures before ligation of the key canthopexy suture when placed through scalp or upper lid access and through subcanthal incisions. Significant chemosis (conjunctival edema) develops after that suture ligation, making lower lid skin closure and tarsorrhaphy suture placement difficult (but not impossible). When placed through a subcanthal incision, both key canthopexy suture ligations, plus the lateral orbicularis suture ligation, must precede lid closure. Advance placement of the temporary tarsorrhaphy sutures (especially laterally at the level of the lateral limbus) is extremely helpful.

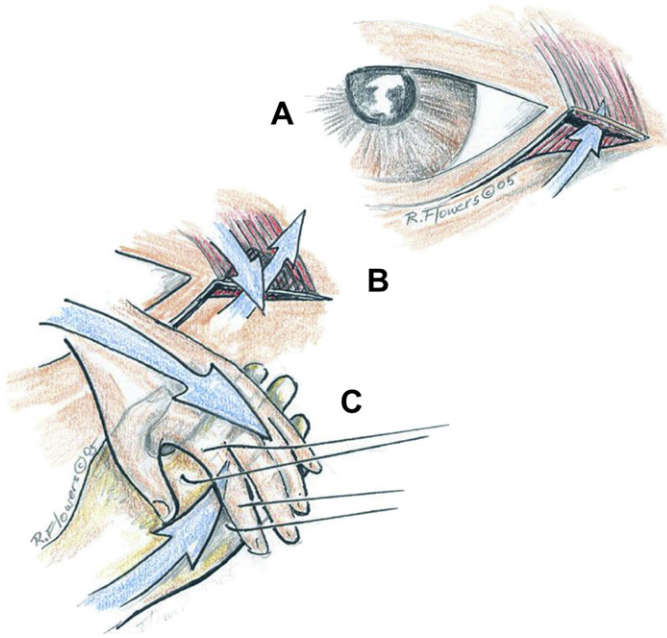


Fig. 47. (A) The incised lower orbicularis flap drawn up underneath the upper orbicularis muscle. To avoid dimpling (B), pull the upper orbicularis down over the lower orbicularis and suture the overlapping upper muscle to the lower muscle, as illustrated in (C), using overlapping hands with “sutures” securing them together.

To assure there is no dimpling lateral to the canthi where the split orbicularis tucks up under itself, additional 6-0 Vicryl (tapered) sutures close off the potential space between the overlapping muscle (**Fig. 47**). This suture is important for all canthopexy access routes. Although the sutures may be interrupted, the authors prefer a running one beginning with the first knot securing the orbicularis to the periosteum of the orbital rim (**Fig. 48**), also incorporating the “key” canthopexy suture as it loops around the orbital rim (not shown in drawing). For clarity of the illustration, interrupted sutures substitute for the running suture actually used. The orbicularis closure suture(s) must (also) be ligated before skin closure, as is true for all the other deep canthopexy sutures.

Start the closure laterally to minimize the bunching that occurs frequently at the lateral extent of lower lid incisions. With a large flap or upper lid canthopexy access, it is acceptable to delay placement of one or two temporary tarsorrhaphy sutures until after skin incisions are closed. Put one or two sutures on each side, near the lateral limbus (lateral border of the iris), and a possible second one in the medial eyelid depending on the amount of chemosis present and predicted (see **Fig. 46**). Ligate these sutures securely with bow knots, allowing easy release for daily inspection until the chemosis totally disappears, allowing tarsorrhaphy suture removal. The tarsorrhaphy sutures should remain ligated until the conjunctival

edema (chemosis) clears, which happens sooner medially than laterally. This program prevents drying out of the bulging edematous conjunctiva and prolonged chemosis and protects against corneal surface defects. Medial tarsorrhaphy sutures usually come out on the first or second day after surgery, allowing vision although it is restricted. The lateral sutures usually stay until the third, fourth, or fifth day after surgery or until chemosis

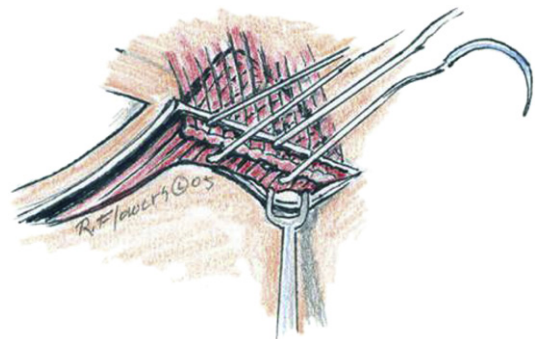


Fig. 48. The actual suturing together of the orbicularis is with 6-0 Vicryl, either interrupted or running. The first suture placed is over the orbital rim and incorporates either the periosteum or key Monocryl suture as it wraps around the orbital rim or both (not shown in drawing). Interrupted sutures are shown for clarity, but, in actuality, a running suture is used.

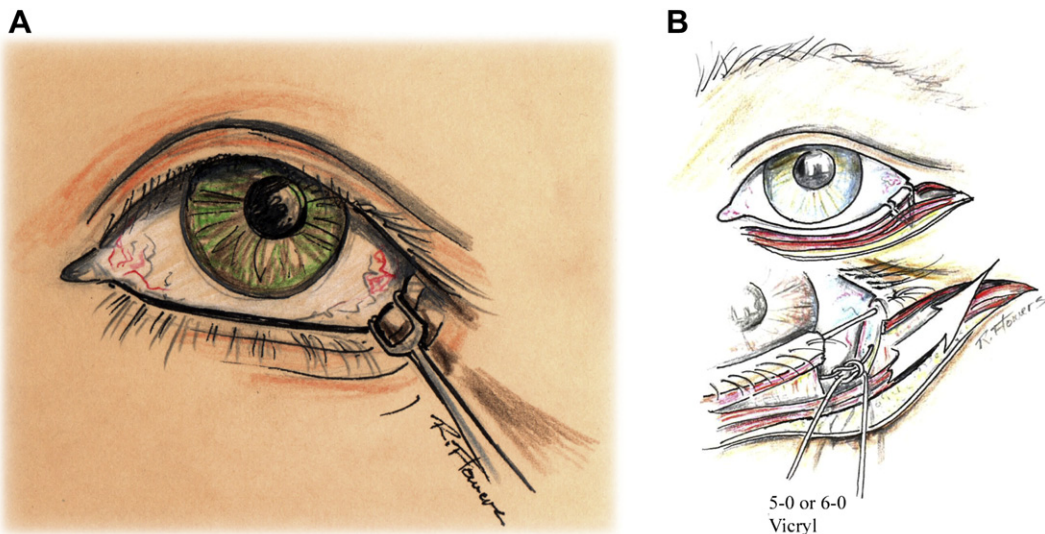


Fig. 49. In persons with stretched out lower lids and excessive length (A), the removal of a lid-shortening wedge of inner lamella (tarsus and conjunctiva) is essential. (B) The wedge resection shown here must be combined with the same type of canthopexy sutures described earlier. Occasionally, the removal of a nasal wedge of lower lid skin and orbicularis is necessary to avoid excess tissue laterally (and is closed with 6-0 Vicryl and 6-0 Prolene). The lower lid closure should be started laterally to avoid a "dog ear" and the suturing advanced nasally.

subsides. Forty-five degrees of upper body elevation during sleep is immensely important in speeding the disappearance of troublesome edema and chemosis. A more stable support than pillows is necessary to keep the upper body elevated.

POTENTIAL CAUSES OF CANTHOPEXY FAILURE

In the occasional patient in whom the lid is stretched and possesses excessive length, a lid-shortening (wedge removal of inner lamella-tarsus and conjunctiva) is necessary for a good result.

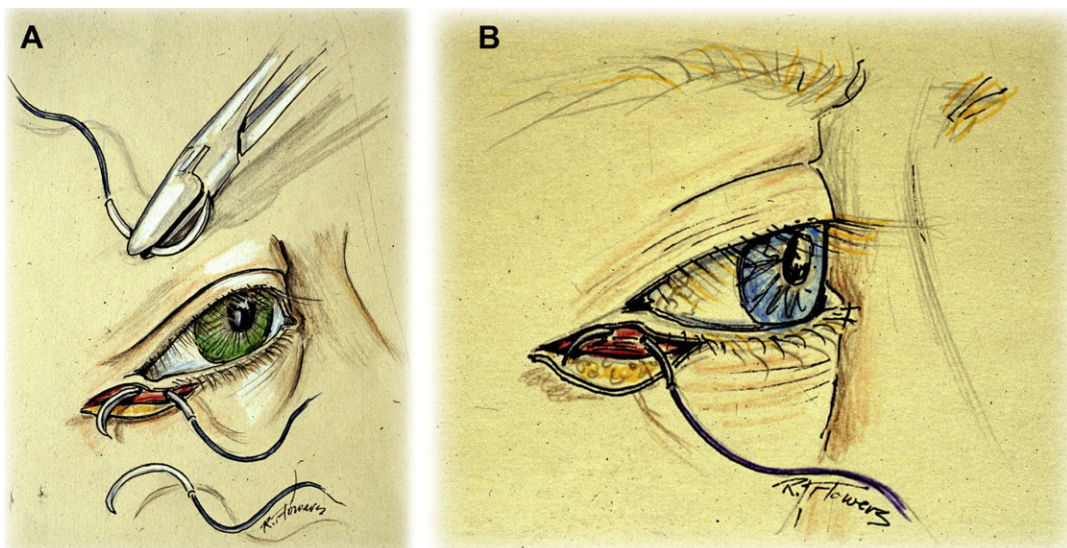


Fig. 50. (A) Cutting needles can wreck a canthopexy, especially with more than one pass. (B) Thin-skinned people of Northern European descent with fragile skin and connective tissue are especially susceptible to this problem. One should be certain in these patients that the canthopexy has a solid grasp of tissue with integrity without violating the conjunctiva. Sometimes a double loop of the canthopexy suture is necessary, as shown in the patient in Fig. 23.

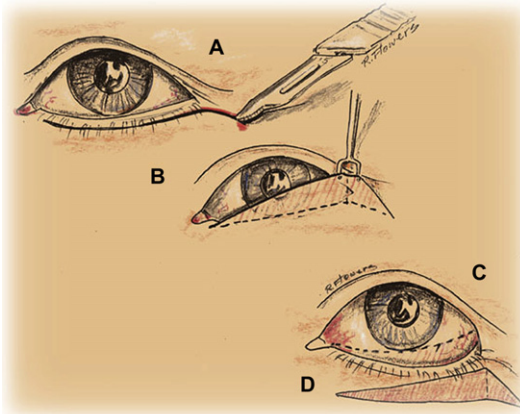


Fig. 51. (A–D) Another cause of failure is excessive skin or skin-muscle removal on the lower lid, sabotaging the tentative correction with downward stress on the lids and lateral canthus. One should be conservative in skin removal. It is tempting to remove more than the midcheek-canthopexy lift can accommodate.

Alternatively, the lid can be shortened, preserving a “tarsal flap” for enhanced attachment to the orbital rim, but there is rarely a need to resort to this technique (Fig. 49). Many canthopexy failures are directly attributable to unaddressed lids of excessive length; but never shorten any lower eyelids in an attempt to restore tone without a concomitant canthopexy that restores length, position, and normal tilt.

Another cause of failure is the wrecking of canthopexy integrity by multiple passes through the tendon and reticular tissues with a cutting needle as opposed to a taper needle. Thin-skinned people of Northern European descent with their scant and fragile connective tissue, persons on long-term steroid therapy, and especially those combining these two characteristics are especially vulnerable to this type of problem. Take special care in this group of people that the canthopexy suture has a solid grasp of tissue with integrity without violating the conjunctiva (Fig. 50). Sometimes a double purchase of the tendon and reticular tissue with the suture before exiting the bone adds a safety factor to the repair.

One more cause of failure is excess skin or skin-muscle removal on the lower lid, encouraged by overestimating the “lifted” effect that results from the supine position or the deceiving “lifted” appearance of an inadequate periosteal canthopexy, sabotaging the tentative correction when the downward stress on the lids overcomes an inadequate repair (Fig. 51).

Release of the tarsal strap and other downward tethering connective tissue bands (Fig. 52) is important to great outcomes. These “bands”

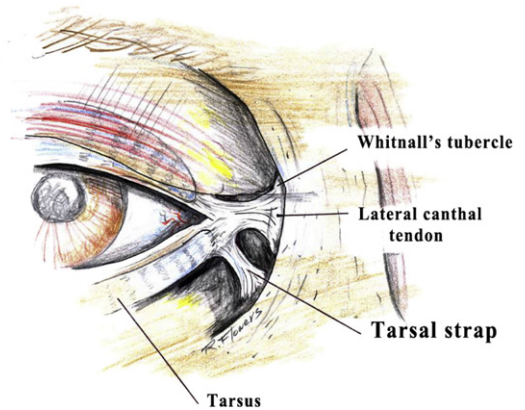


Fig. 52. Releasing the tarsus strap³⁴ and any other downward tethering connective tissue bands in the inferior lateral orbital area is helpful, if not essential, to long lasting and secure canthopexies.

tether the lateral tarsal border and canthus down toward the lower lateral orbital wall, making effective, long-lasting canthopexy unlikely unless released. The capsulo-palpebral fascia will also require release in some patients, especially in those who have iatrogenically induced dystopia.

Exophthalmos, or malar hypoplasia causing “hemi-exophthalmos” (exophthalmos of the lower half of the globe), poses another source of a poor result (Fig. 53). Elevation of the lateral canthal attachment must accompany almost all lower lid-tightening procedures in these patients, except for Kuhnt-Szymanowski type procedures. Often,

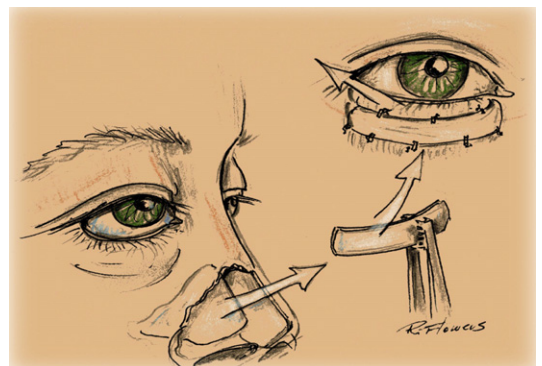


Fig. 53. Exophthalmos and malar hypoplasia causing hemi-exophthalmos (exophthalmos of the lower half of the globe) pose another source of a poor result. Elevation of the lateral canthal attachment must accompany almost all lid-tightening procedures in these patients. Often, the addition of a spacer interposed between the tarsus and lower lid retractors is necessary to successfully solve the lid posture problem. Orbital expansion or fat reduction to reduce globe prominence can be extremely helpful.

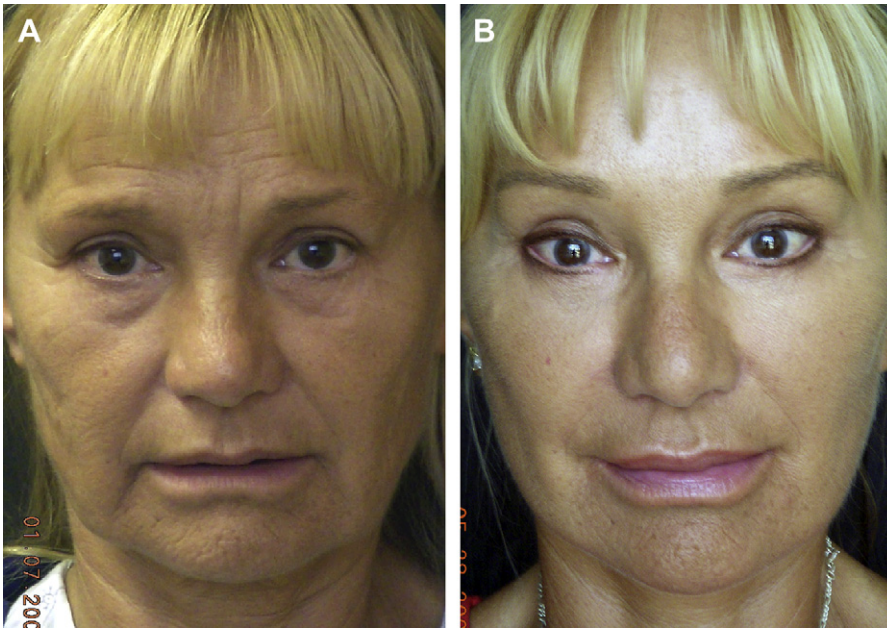

Fig. 54. A 59-year-old woman (A) before (two previous lower lid blepharoplasties were done elsewhere) and (B) 2 months after a Mag-5 and facelift were combined.

the addition of a spacer interposed between the tarsus and lower lid retractors is necessary to successfully solve the lid posture problem. Orbital expansion or fat reduction to reduce globe prominence is also extremely helpful.³⁶ Tarsal strip operations are rarely necessary, but saving the excess

tarsus in long lower lid reduction may add helpful length in the presence of prominent globes, whether true exophthalmos or hemi-exophthalmos; however, one should be aware that tarsal strip repairs shorten the aperture in normal eyes of normal prominence.

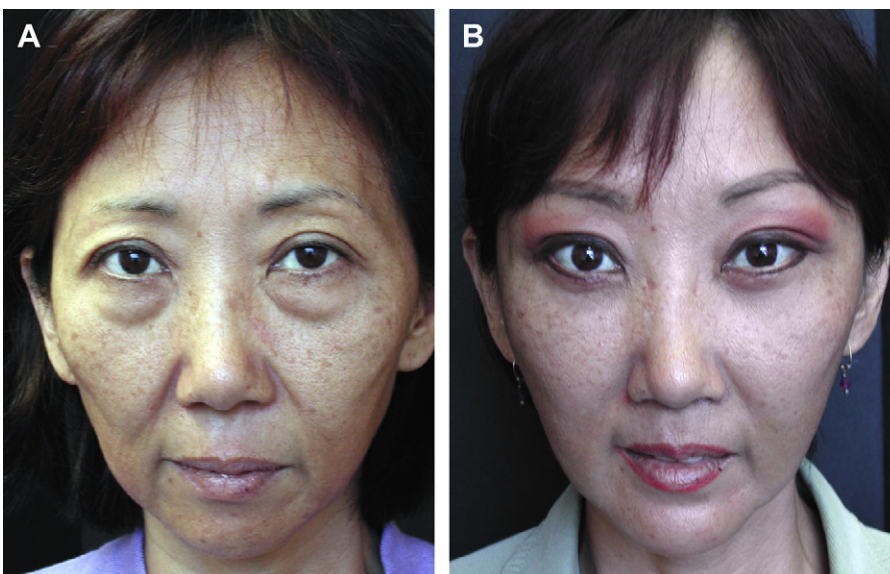


Fig. 55. A 48-year-old woman (A) before and (B) 1 year after Mag-5. No blepharoplasty or other procedures were performed, and no fillers or implants were used in the tear trough area.

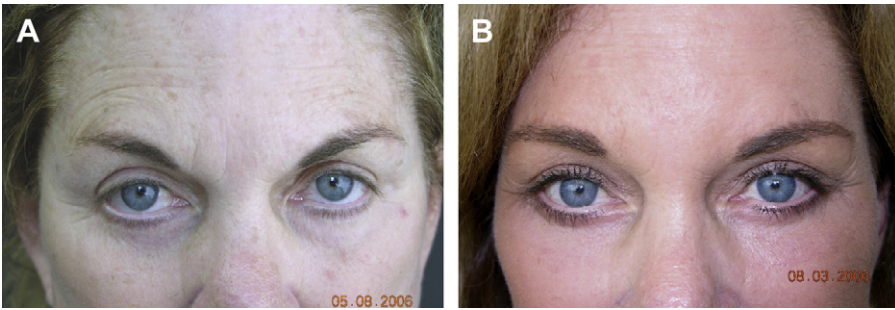


Fig. 56. A 53-year-old woman (A) preoperatively, with two previous lower lid blepharoplasties (done elsewhere) and vertical dystopia, rounding of the eyes, and intercanthal axis drop. (B) Two years after Mag-5 (no other surgeries).

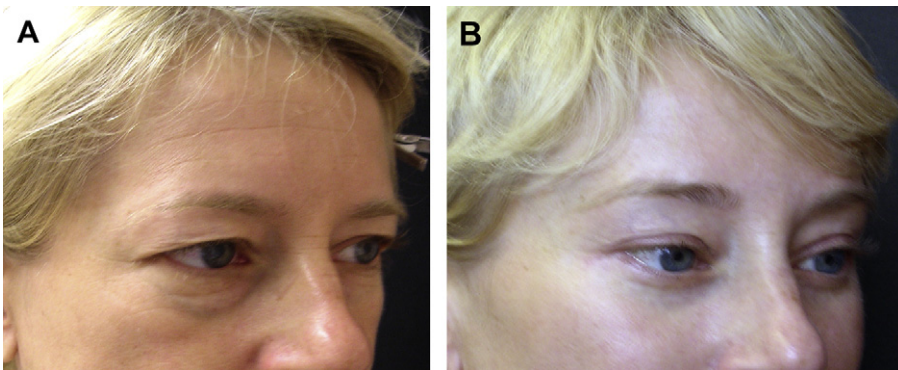


Fig. 57. A 42-year-old woman (A) before and (B) 1 year after Mag-5, with tear trough implants, upper lid blepharoplasty, and Valentine anguloplasty. Also shown preoperatively in Fig. 14.

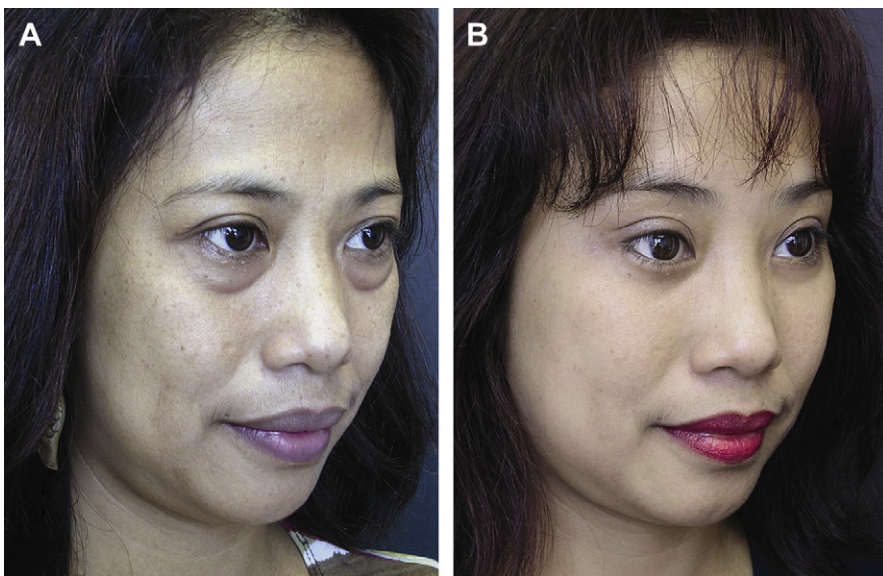

Fig. 58. A 43-year-old woman (A) before and (B) 1 year after Mag-5. Note the correction of her tear trough deformities without implants and without any other treatment or fillers.

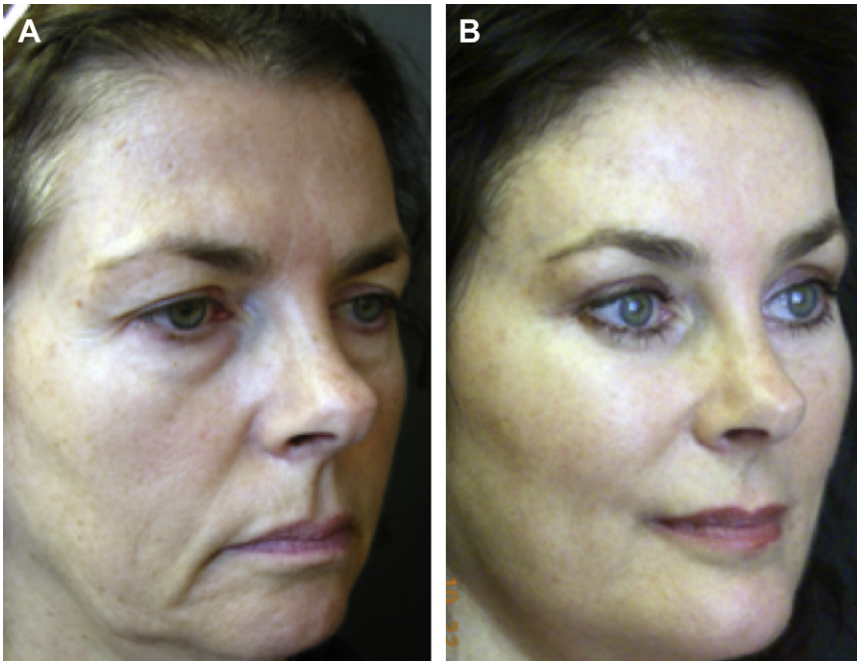


Fig. 59. A 51-year-old woman (A) before and (B) 1 year after Mag-5 and a facelift. Note the correction of her tear trough deformities without implants and without any other treatment or fillers.

EXPERIENCE

Since 1975, coronal lift with canthopexy releasing the tarsal strap and tethering connective tissue has been among the senior surgeon's most common operations, totaling in excess of 2000 patients. The number of patients with full malar periosteal elevation and release exceeds 500. **Figs. 54–56** show three representative patients.

Subsequent lateral upper face “booster excisions” or other lateral lifting procedures occurred in 10% of the 2000 patients; many of these procedures were performed 25 or more years after the original operation.

Tear trough implants were added to 135 of these patients (**Fig. 57**) and to over 270 other patients. Only one patient required implant position modification owing to malposition during a backup generator power loss while finishing the second side. We are aware of no removals for pain, infection, or deformity, nor for any other reason in our series. A delightful discovery was that mild-to-moderate tear trough deformities were beautifully corrected by the Mag-5 operation (**Figs. 58–60**). None of these patients had tear trough implants or any other type of facial filler in the tear trough or nasojugal areas.

There were two short-term unilateral upper lip palsies with the Mag-5 operations. Both of these

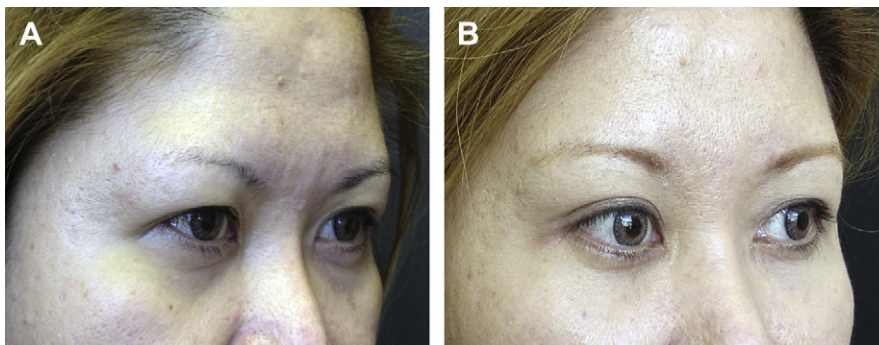


Fig. 60. A 39-year-old woman (A) before and (B) 1 year after Mag-5. Note the correction of her tear trough deformities without implants and without any other treatment or fillers.

patients had histories of previous palsy on the same side after earlier malar surgery performed elsewhere.

The Mag-5 is a superb operation that beautifully addresses defects not only of birth, development, and aging but also of traumatic and iatrogenic origin.

SUMMARY

The Mag-5 is the premiere rejuvenating and restorative operation in esthetic surgery. It can be *transformative* as well but only when, and if, *transformation* is the goal. Its five surgical components are joined in one operation to address the upper and midface and the periorbital area, but it also reaches down to the lower cheek and upper neck area for a more excellent and longer lasting outcome. Its components include a lateral emphasis frontal lift (according to the surgeon's choice) with corrugator resection, lower blepharoplasty, and extended two-layered canthopexy, with a partial to full subperiosteal malar release midcheek lift assisted by an absorbable suture securing the malar tuft periosteum and fibrous tissue to the orbital rim.

This combined procedure lifts the globe, sucks in and then restrains the lower orbital fat, helps fill in upper orbital hollows, usually eradicates nasojugal grooves, covers up mild-to-moderate tear trough groove deformities without the need for implants or fillers, lifts lower cheek sag, eliminates most lid and cheek wrinkles, enhances malar fullness, eliminates malar fat pads and festoons, lifts the corners of the mouth, and beautifully corrects the upper face.

REFERENCES

1. Flowers RS. Aesthetic surgery in the oriental: current trends in plastic surgery. In: Marsh J, editor. Current therapy in plastic and reconstructive surgery. vol. I. Philadelphia: BC Decker; 1989.
2. Flowers RS, Nassif J. Aesthetic periorbital surgery. In: Mathes S, editor. Plastic surgery. 2nd edition. vol. II. Philadelphia: Elsevier; 2006. p. 96–100.
3. Flowers RS. Advanced blepharoplasty: principles of precision. In: Zaoli G, Meyer R, Gonzales-Ulloa M, et al, editors. Aesthetic plastic surgery. vol. II. Padova (Italy): Piccin Press; 1987. p. 115–41.
4. Flowers RS. The art of eyelid and orbital aesthetics. Clin Plast Surg 1987;14:709.
5. Flowers RS. Blepharoplasty and brow lifting. In: Roenigk RK, Roenigk HH, editors. Principles of dermatologic surgery. New York: Marcel Dekker; 1989.
6. Flowers RS. Blepharoplasty and coronal-canthopexy. Teleplast symposium video, Plastic Surgery Educational Foundation Audiovisual Library, created in 1987.
7. Flowers RS. Blepharoplasty. In: Courtiss E, editor. Male aesthetic surgery. St. Louis (MO): CV Mosby; 1981. p. 203.
8. Flowers RS. Blepharoplasty: management of complications and patient dissatisfaction. In: Goldwyn RM, editor. The unfavorable result in plastic surgery: avoidance and treatment. vol. 2. 2nd edition. Boston: Little, Brown; 1984.
9. Flowers RS. The biomechanics of brow and frontalis function and its effect on blepharoplasty. Clin Plast Surg 1993;20:255.
10. Flowers RS. Blepharoplasty. In: Weinzeig J, editor. Plastic surgery secrets. Philadelphia: Hanley & Belfus; 1999. p. 276–86.
11. Flowers RS. Colloquium. Clin Plast Surg 1978;1: 66–9.
12. Flowers RS. Cosmetic blepharoplasty—state of the art. In: Habal MD, editor, Advances in plastic and reconstructive surgery. vol. 8. Chicago: Mosby—Year Book; 1992. p. 51–66.
13. Flowers RS. The open approach to forehead and brow lifting. Aesthetic Surgery Journal 1998;18(6):463–4.
14. Flowers RS, DuVal C. Blepharoplasty and periorbital aesthetic surgery. In: Aston SJ, Beasley RW, Thorn CHM, editors. Grabb and Smith's plastic surgery. Fifth Edition. Philadelphia: Lippincott-Raven; 1997. p. 609–30.
15. Flowers RS. Precision planning in blepharoplasty: the importance of preoperative mapping. Clin Plast Surg 1993;20:303–10.
16. Flowers RS. Canthopexy as a routine blepharoplasty component. Clin Plast Surg 1993;20:351.
17. Postgraduate courses on blepharoplasty, periorbital aesthetic surgery, coronal lifts and canthopexy and canthopexy extended into mid-cheek lifts given annually at the meetings of the American Society for Aesthetic Plastic Surgery, 1975 through 2008, and at the American Society of Plastic Surgeons, 1974 through 2002, and semiannually 2002 through 2007.
18. Flowers RS. Lower eyelids and troughs. Presentation by invitation at the Annual Meeting of the American Society for Aesthetic Plastic Surgery. San Diego, May 2008.
19. Flowers RS. Routine canthopexy with lower blepharoplasty. Presentation at the Annual Meeting of the American Society of Plastic Surgeons. Los Angeles, 1980.
20. Flowers RS. Bicentennial blepharoplasty. Personally animated movie in the Film Library of the American Society of Plastic Surgeons. Shown by invitation at the Annual Meeting of American Society of Plastic Surgeons. Boston, 1976.
21. Flowers RS. The tear trough deformity and its correction. Essay presented at the Annual Meeting of the California Society of Plastic Surgeons. Monterey, California, 1972.

22. Flowers RS. Subgaleal grafts. Essay presented at the Annual Meeting of the American Society for Aesthetic Plastic Surgery. New Orleans, 1986.
23. Flowers R. Blissful blepharoplasty, including correction of tear trough defects. Invited lecture at the International Society for Aesthetic Plastic Surgery Congress. Mexico City, 1974.
24. Wolff E. The anatomy of the eye and orbit. Philadelphia: WB Saunders; 1976.
25. Loeb R. Fat pad sliding a fat grafting for leveling depression. *Clin Plast Surg* 1981;8:757–76.
26. Loeb R. Improvements in blepharoplasty: creating a flat surface for the lower lid. In Transactions of the 7th International Congress of Plastic and Reconstructive Surgery. Rio de Janeiro, Brazil, May 20–25, 1979. Rio de Janeiro (Brazil): Cart Craft; 1979. p. 390–3.
27. Loeb R. Naso-jugal groove leveling with fat tissue. *Clin Plast Surg* 1993;20:393–400.
28. Jelks GW, Glat PM, Jelks EB, et al. The interior retinacular lateral canthoplasty: a new technique. *Plast Reconstr Surg* 1997;100:1262.
29. Jelks GW, Jelks EB. The influence of orbital and eyelid anatomy of the palpebral aperture. *Clin Plast Surg* 1991;18:183.
30. Zide BM, Jelks GW. Surgical anatomy of the orbit. New York: Raven Press; 1985.
31. Flowers RS. Invagination blepharoplasty. In Transactions of the Sixth International Congress of Plastic and Reconstructive Surgery. Paris: Masson; 1975. p. 45.
32. Beard C. Ptosis. St. Louis (MO): CV Mosby; 1976.
33. Beard C, Quickert MH. Anatomy of the orbit. New York: Aesculepius; 1969.
34. Flowers RS, Nassif JM, Rubin AD, et al. A key to canthopexy: the tarsal strap. A fresh cadaveric study. *Plast Reconstr Surg* 2005;116(6):1752–60.
35. Flowers RS, Ceydeli A. The open coronal approach to forehead rejuvenation. *Clin Plast Surg* 2008;35(3): 331–51; discussion 329.
36. Stark B, Olivari N. Treatment of exophthalmos by orbital fat removal. *Clin Plast Surg* 1993;20(2): 285–9.