

When Should We Order a CT Scan and When Should We Rely on the Results to Diagnose an Acute Appendicitis?

Adil Ceydeli, MD,*[†] Simon Lavotshkin,[†] Jack Yu, MD,* and Leslie Wise, MD[†]

*Division of Plastic Surgery, Medical College of Georgia, Augusta, Georgia, and [†]Department of Surgery, New York Methodist Hospital, Brooklyn, New York

OBJECTIVE: The objective of this study was to retrospectively analyze the last 100 consecutive emergency appendectomies performed in the authors' institution, which is a community-based teaching hospital, and look at the accuracy of the CT scan in the diagnosis of acute appendicitis.

DESIGN: Retrospective clinical study.

SETTING: A 600-bed community-based teaching hospital.

METHODS: The last 100 consecutive emergency appendectomies, which were performed at New York Methodist Hospital in 2004, were retrospectively analyzed. The collected data included the demographics of the patients, relevant history, physical examination, laboratory and radiological tests, and pathology results.

The statistical analyses were performed using the JMP version 3.2 software (SAS Institute Inc., Cary, North Carolina). An alpha value of 0.05 was used in all statistical analyses, and p values were considered as being statistically significant at or below the alpha value of 0.05.

RESULTS: There was no statistically significant correlation between the acute appendicitis and some of the typical presenting symptoms and signs of acute appendicitis (rebound tenderness, low-grade fever, elevated white blood cell count, and anorexia).

The sensitivity, specificity, positive predictive value, and negative predictive value of the CT scan in this retrospective analysis were 96%, 75%, 98.5%, and 50%, respectively, with an overall efficiency of 95%. However, the sensitivity, specificity, positive predictive value, and negative predictive value of the CT scan increased after reevaluation of the false-positive, false-negative, and inconclusive CT results by an experienced radiologist in a blind fashion (97%, 100%, 100%, and 71%, respectively). The correlation between the CT scan and the

pathology result was statistically significant when the CT result was positive or negative ($p = 0.0001$).

CONCLUSION: The CT scan is indicated when the clinical presentation is equivocal, and it will be helpful if the result is positive or interpreted as negative only by an experienced radiology attending. (Curr Surg 63:464-468. © 2006 by the Association of Program Directors in Surgery.)

KEY WORDS: acute appendicitis, CT scan, CAT scan, negative appendectomy, appendectomy, computerized tomography

INTRODUCTION

Acute appendicitis is the most common acute surgical condition of the abdomen. Periumbilical abdominal pain, eventually localizing to the right lower quadrant with peritoneal signs, low-grade fever, anorexia, and elevated white blood count is the typical textbook presentation of a patient with acute appendicitis.¹ However, not every patient has a typical clinical presentation and not every patient with typical presentation has acute appendicitis, which makes the diagnosis of acute appendicitis still challenging.

Historically 15% to 20% of negative appendectomies were acceptable in order to prevent the increased morbidity and mortality of perforated appendicitis and diffuse peritonitis. There has been and still is a great interest in the literature to decrease the negative appendectomy rate by using a computed tomography (CT) scan, while preventing the complications of undiagnosed appendicitis, which could lead to gangrene and perforation if left untreated.

There are 2 schools of thought regarding the use of CT scan for the diagnosis of acute appendicitis: one supporting its routine use due to the decreased incidence of negative appendectomies, and the other one against its routine use due to the increased cost and delay in surgical management.

The objective of this study was to retrospectively analyze the last 100 consecutive emergency appendectomies performed in the authors' institution, which is a community-based teaching

Correspondence: Inquiries to Adil Ceydeli, MD, MS, Division of Plastic Surgery, Medical College of Georgia, 1467 Harper Street, HB-5040, Augusta, GA 30912; e-mail: adilc@excite.com

hospital, and look at the accuracy of CT scan in the diagnosis of acute appendicitis.

MATERIALS AND METHODS

The last 100 consecutive emergency appendectomies, which were performed at New York Methodist Hospital in 2004, were retrospectively analyzed. The collected data included the demographics of the patients, relevant history (anorexia/nausea/vomiting), physical examination (peritoneal signs, temperature, and heart rate on admission), laboratory and radiological tests (white blood cell count and preoperative computed tomography scan using double contrast), and pathology results. All surgical specimens were evaluated histologically by an attending pathologist. The CT scans, which were done during the night, were initially read by a PGY1-3 radiology resident on call (inexperienced radiologist); however, all studies were reported officially by a radiology attending. The statistical analyses were initially performed according to the official CT scan results reported, but the data were reanalyzed after the false-positive, false-negative, and inconclusive CT scan results were reevaluated by an experienced radiology attending, who was advanced fellowship trained in body imaging, in a blind fashion.

The same clinical history was provided to both radiologists, which consisted of right lower quadrant pain to rule out acute appendicitis.

The statistical analyses were performed using the JMP version 3.2 software (SAS Institute Inc., Cary, North Carolina). The nominal data were cross-classified in a contingency table and analyzed using the chi-square distribution and likelihood ratio test. The continuous data were analyzed using the one-way analysis of variance (ANOVA) table, and the means were compared using Student's t-test. An alpha value of 0.05 was used in all statistical analyses, and p values were considered as being statistically significant at or below the alpha value of 0.05.

RESULTS

The last 100 consecutive patients, who underwent appendectomy in 2004 with the preoperative diagnosis of acute appendicitis, were included in the study. The incidental and interval appendectomies were excluded. Fifty-seven procedures were performed laparoscopically, whereas 42 of them were performed through right lower quadrant incision. One case was converted to open.

Demographics

The age of the patients ranged between 4 and 66 years, and 59% of the patients were men. Mean age of the patients was 29 ± 2 and 27 ± 5 years in acute appendicitis and negative appendectomy groups, respectively, and there was no statistically significant age difference between these 2 groups ($p = 0.65$).

Symptoms, Signs, and Laboratory Findings

Only the symptoms, signs, and laboratory findings in the emergency room admission were included in the statistical analyses (Table 1).

There was no significant difference between the acute appendicitis and negative appendectomy groups in any of the symptoms, signs, and laboratory findings investigated (Table 1).

Computed Tomography (CT) Scan Findings

Overall, 100 patients underwent emergency appendectomy with the provisional diagnosis of acute appendicitis (Fig. 1). A total of 79 patients in the study group had a CT scan. Of these 79 patients, 69 patients had CT findings of acute appendicitis, 4 patients had an inconclusive study, and 6 patients had no CT signs of appendicitis. The negative appendectomy rate in the 79 patients with a CT scan preoperatively was 7.6%. A CT scan was not obtained preoperatively in 21 patients, and 5 of these patients (24%) had negative appendectomies.

Overall, 68 patients with the positive CT findings had histologically confirmed acute appendicitis (true positive), and only 1 patient with positive CT findings ($n = 1$) did not have appendicitis (false positive). The correlation between the positive CT findings and positive histopathologic findings of acute appendicitis was statistically significant ($p = 0.0001$).

The CT scan was negative in 6 patients, in which 3 of these patients had appendicitis (false negative), and the other 3 had negative appendectomies (true negative). There was no significant correlation between the CT result and pathology result if the CT was inconclusive or negative.

The sensitivity, specificity, positive predictive value, and negative predictive value of the CT scan in this retrospective analysis were 96%, 75%, 98.5%, and 50%, respectively, with an overall efficiency of 95%.

There were a total of 4 inconclusive, 3 false-negative, and 1 false-positive CT results. These 8 studies were reevaluated by an experienced radiologist, who was fellowship trained in body

TABLE 1. Symptoms, Signs, and Laboratory Findings in Acute Appendicitis and Negative Appendectomy Groups

	Acute Appendicitis Group (n = 89)	Negative Appendectomy Group (n = 11)	p Value
Anorexia/nausea/vomiting	75 (84%)	10 (91%)	0.53
Rebound tenderness	33 (37%)	4 (37%)	0.96
Temperature (°F)	98.8	99.5	0.11
Heart rate (bpm)	92	102	0.11
White blood cell count (K)	14.5	14.2	0.79

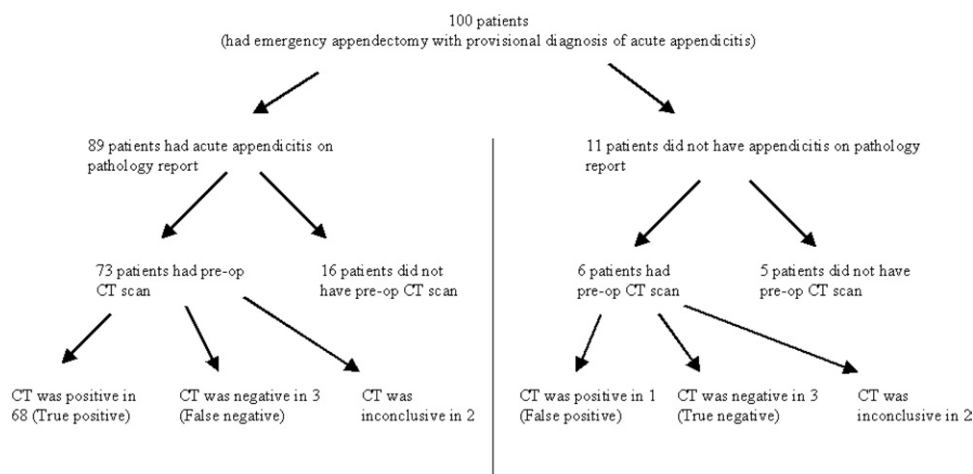


FIGURE 1. The pathology results and CT findings of the 100 patients.

imaging, in a blind fashion, and after the second evaluation, there were only 3 inconclusive, 2 false-negative, and 0 false-positive CT results. When the data were reanalyzed according to these new results, the sensitivity of the CT scan increased to 97% from 96%, the positive predictive value increased to 100% from 98.5%, the specificity increased to 100% from 75%, and the negative predictive value increased to 71% from 50% (Table 2). The correlation between the CT scan and the pathology result was statistically significant when the CT result was positive or negative ($p = 0.0001$).

DISCUSSION

Appendectomy is one of the most common general surgical procedures performed in the United States; however, diagnosing the acute appendicitis remains challenging despite the increased use of the CT scan and ultrasonography.

There has been, and still is, a great interest in the literature in the accuracy of the CT scan to diagnose acute appendicitis to prevent unnecessary negative laparotomies. There are mainly 2 schools of thoughts: one supporting its routine use²⁻¹¹ and the other against it,¹²⁻¹⁶ reserving it for selected cases, which shows the ongoing debate in the literature and the absence of an accepted standard of care in this matter.

The supporters of the CT scan to diagnose acute appendicitis argue that the CT scan is a highly sensitive and specific test,

which will decrease the negative appendectomy rates, thus reducing the hospital cost² without delaying surgery in cases of true appendicitis. The pro-CT scan group published a sensitivity rate ranging 92% to 99% and a specificity rate of 88% to 100%.³⁻⁹ The negative appendectomy rate may be as high as 38% in certain patient populations (women of child-bearing age) with clinical diagnosis alone.¹⁷ With the advent of the CT scan, the negative appendectomy rate may be reduced to as low as 2%.¹¹

On the other hand, there are studies in the literature showing no significant change in the negative appendectomy rates even with the liberal use of the CT scan.¹²⁻¹⁵ The anti-CT scan group further argues that the use of the CT scan for diagnosing acute appendicitis significantly increases the emergency room and hospital stay, delays the interval before surgical intervention, and increases the cost, while not helping to reduce the negative appendectomy rates; thus, its routine use is not warranted.¹²⁻¹⁵

This retrospective study showed that the negative appendectomy rate was much less in the CT group (7.6%) than in the non-CT group (24%), and the CT scan for diagnosing the patients with acute appendicitis had a high sensitivity (96%), positive predictive value (98.5%), and overall efficiency (95%); however, the specificity and negative predictive values were very low (75% and 50%, respectively). However, when the incon-

TABLE 2. The Sensitivity, Specificity, Positive, and Negative Predictive Values of the CT Scan for Acute Appendicitis

	CT Interpretation by Inexperienced Radiologist	CT Interpretation by Experienced Radiologist
False-negative results	3	2
False-positive results	1	0
Inconclusive results	4	3
Sensitivity	96%	97%
Specificity	75%	100%
Positive predictive value	98.5%	100%
Negative predictive value	50%	71%

clusive, false-negative, and false-positive studies were reevaluated by an experienced radiologist, the sensitivity, specificity, positive, and negative predictive values all increased to 97%, 100%, 100%, and 71%, respectively (Table 2). The increase in specificity and negative predictive value was particularly significant.

Even though the rebound tenderness, low-grade fever, elevated white blood cell count, and anorexia are some typical presenting symptoms and signs of acute appendicitis in a patient with an abdominal pain, this study failed to show a statistically significant correlation. However, the evaluation of the patient in a timely manner by an experienced surgeon, along with the interpretation of these clinical symptoms and signs on a patient-by-patient basis, is the best way to establish a diagnosis or decide whether the patient needs a CT scan. To gain the clinical experience, the residents in training should not solely rely on the CT scan in their differential evaluation of not only acute appendicitis but also any abdominal pain.¹⁸

The conclusion of the study is not when to order a CT scan, but rather when to rely on a CT scan in diagnosing acute appendicitis. The data suggest that the CT scan is a very accurate test to rule in acute appendicitis when the study is positive; however, when the study is inconclusive or negative, it is interpreter dependant, and its specificity may change significantly depending on the experience level of the radiologist. One may argue that it is common sense that the readings of a CT scan may differ between an attending or resident radiologist, and all CT scans should be read by an attending radiologist. This would be ideal in a perfect setting; however, in this community-based hospital, as well as in many hospitals across the United States, the initial CT scans are read by radiology residents, especially late at night. If the reading of the CT scan will dictate the treatment plan, as in equivocal cases of appendicitis, then it is very important to know when to rely on a resident's interpretation, which this study concludes.

CONCLUSION

The evaluation of the patient in a timely manner by an experienced surgeon, along with the interpretation of the clinical symptoms and signs on a patient-by-patient basis, is the best way to establish the diagnosis of acute appendicitis and/or to decide whether the patient needs a CT scan.

The CT scan is indicated when the clinical presentation is equivocal, and it will be helpful if the result is positive or interpreted as negative only by an experienced radiology attending. If the clinical presentation is equivocal and the CT scan is reported by an inexperienced radiologist as negative or inconclusive for acute appendicitis, then one can go either way, operate or observe until an experienced radiologist reevaluates the CT scan, preferably with the presence of the surgical attending; either approach will be acceptable.

REFERENCES

1. Schwartz SI. Appendix. In: Schwartz SI, editor. *Principles of Surgery*. New York: McGraw-Hill; 1994:1307.
2. Rao PM, Rhea JT, Novelline RA, Mostafavi AA, McCabe CJ. Effect of computed tomography of the appendix on treatment of patients and use of hospital resources. *N Engl J Med*. 1998;338:141-146.
3. Stroman DL, Bayouth CV, Kuhn JA, et al. The role of computed tomography in the diagnosis of acute appendicitis. *Am J Surg*. 1999;178:485-489.
4. Balthazar EJ, Rofsky NM, Zucker R. Appendicitis: the impact of computed tomography imaging on negative appendectomy and perforation rates. *Am J Gastroenterol*. 1998;93:768-771.
5. Brandt MM, Wahl WL. Liberal use of CT scanning helps to diagnose appendicitis in adults. *Am Surg*. 2003;69:727-731; discussion 731-732.
6. Wijetunga R, Tan BS, Rouse JC, Bigg-Wither GW, Doust BD. Diagnostic accuracy of focused appendiceal CT in clinically equivocal cases of acute appendicitis. *Radiology*. 2001;221:747-753.
7. Lane MJ, Liu DM, Huynh MD, Jeffrey RB Jr, Mindelzun RE, Katz DS. Suspected acute appendicitis: nonenhanced helical CT in 300 consecutive patients. *Radiology*. 1999; 213:341-346.
8. Poh AC, Lin M, Teh HS, Tan AG. The role of computed tomography in clinically-suspected but equivocal acute appendicitis. *Singapore Med J*. 2004;45:379-384.
9. Cakirer S, Basak M, Colakoglu B, Bankaoglu M. Diagnosis of acute appendicitis with unenhanced helical CT: a study of 130 patients. *Emerg Radiol*. 2002;9:155-161. Epub 2002 May 4.
10. Schuler JG, Shortsleeve MJ, Goldenson RS, Perez-Rossello JM, Perlmutter RA, Thorsen A. Is there a role for abdominal computed tomographic scans in appendicitis? *Arch Surg*. 1998;133:373-376; discussion 377.
11. Jones K, Pena AA, Dunn EL, Nadalo L, Mangram AJ. Are negative appendectomies still acceptable? *Am J Surg*. 2004;188:748-754.
12. Perez J, Barone JE, Wilbanks TO, Jorgensson D, Corvo PR. Liberal use of computed tomography scanning does not improve diagnostic accuracy in appendicitis. *Am J Surg*. 2003;185:194-197.
13. Flum DR, Morris A, Koepsell T, Dellinger EP. Has misdiagnosis of appendicitis decreased over time? A population-based analysis. *JAMA*. 2001;286:1748-1753.

14. Lee SL, Walsh AJ, Ho HS. Computed tomography and ultrasonography do not improve and may delay the diagnosis and treatment of acute appendicitis. *Arch Surg*. 2001;136:556-562.
15. Hong JJ, Cohn SM, Ekeh AP, Newman M, Salama M, Leblang SD, for the Miami Appendicitis Group. A prospective randomized study of clinical assessment versus computed tomography for the diagnosis of acute appendicitis. *Surg Infect (Larchmt)*. 2003;4:231-239.
16. Paulson EK, Kalady MF, Pappas TN. Clinical practice. Suspected appendicitis. *N Engl J Med*. 2003;348:236-242.
17. Borgstein PJ, Gordijn RV, Eijssbouts QA, Cuesta MA. Acute appendicitis—a clear-cut case in men, a guessing game in young women. A prospective study on the role of laparoscopy. *Surg Endosc*. 1997;11:923-927.
18. Ceydeli A. Acute abdominal pain. *Hosp Physician*. 2003;39:11.